
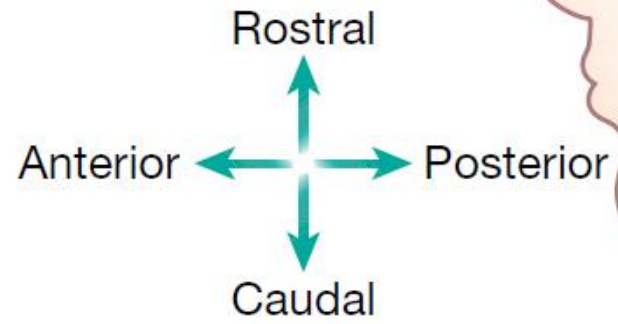
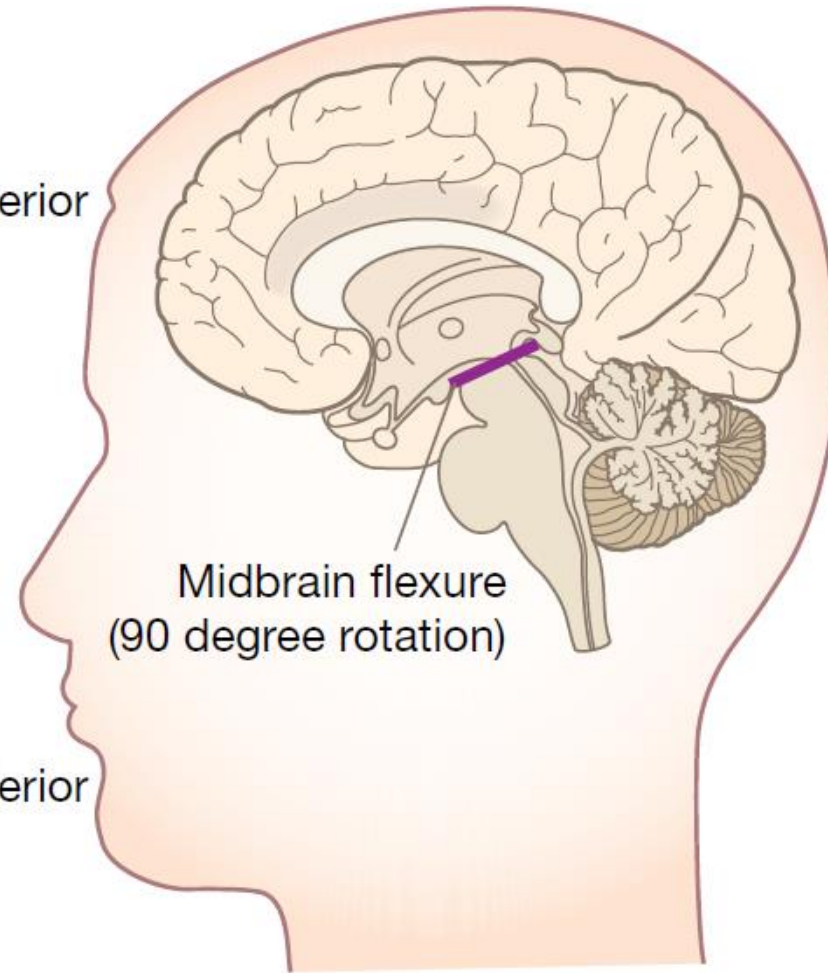
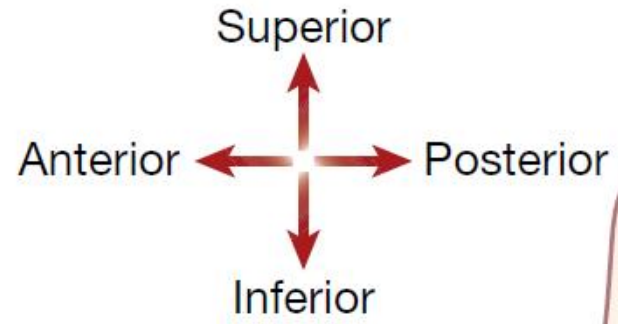


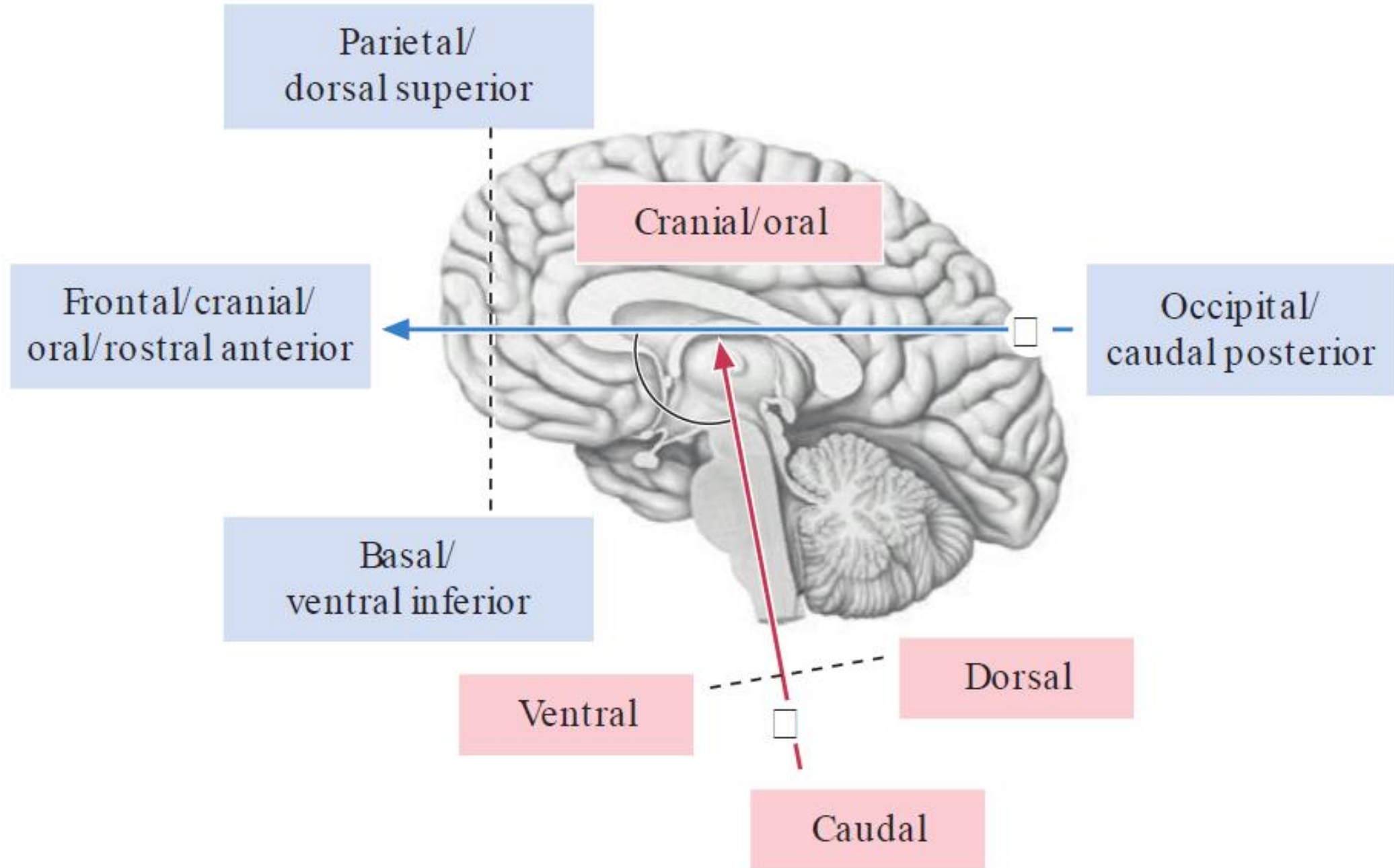
Estructura Interna de los Hemisferios Cerebrales

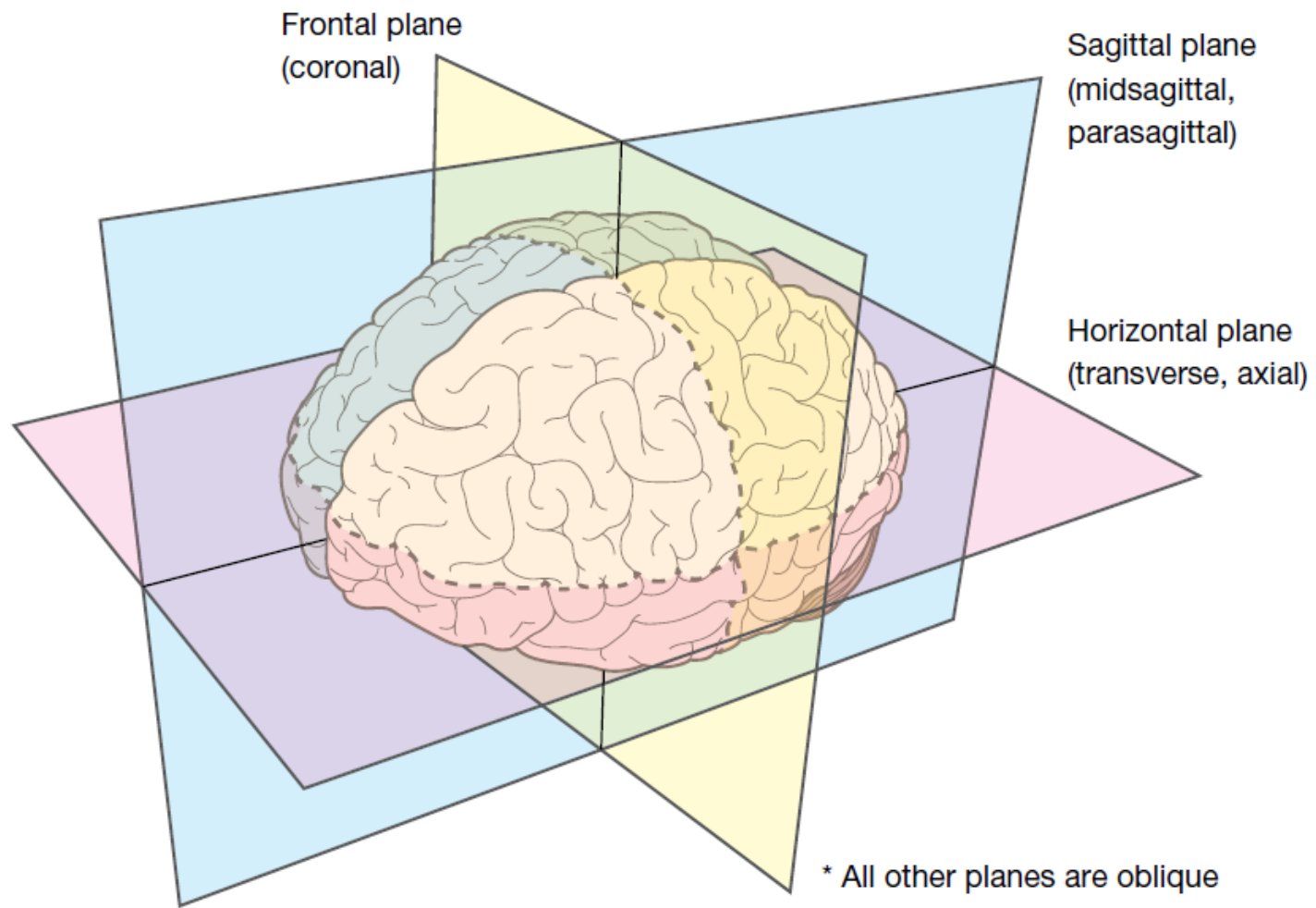
Nelson D. Villalba M.D. M.Sc.



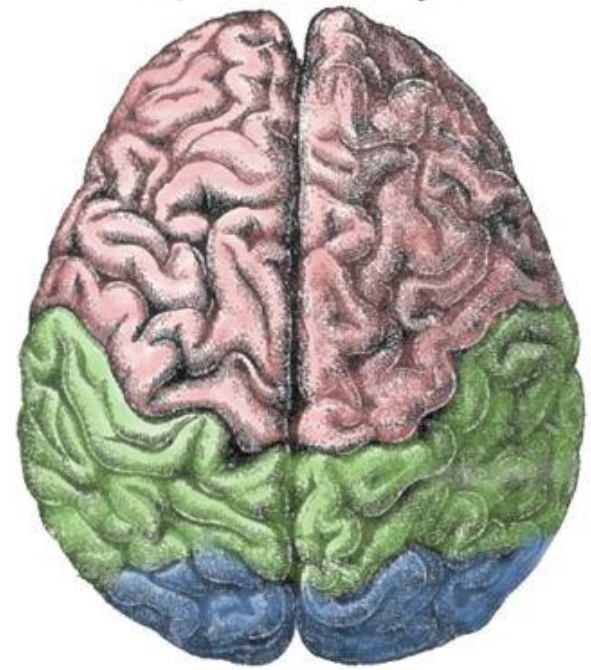


Antes de seguir, Recuerden que...



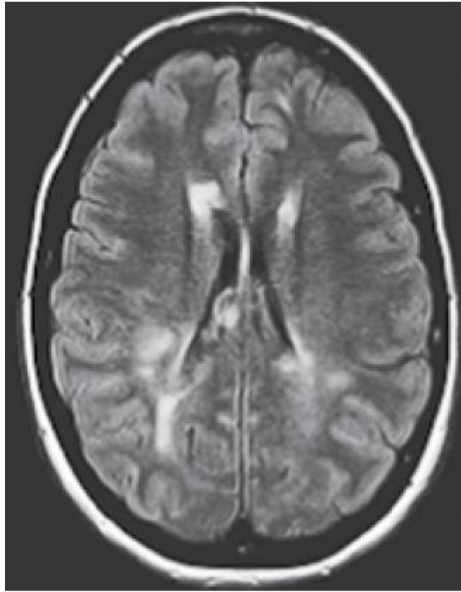


Lateral

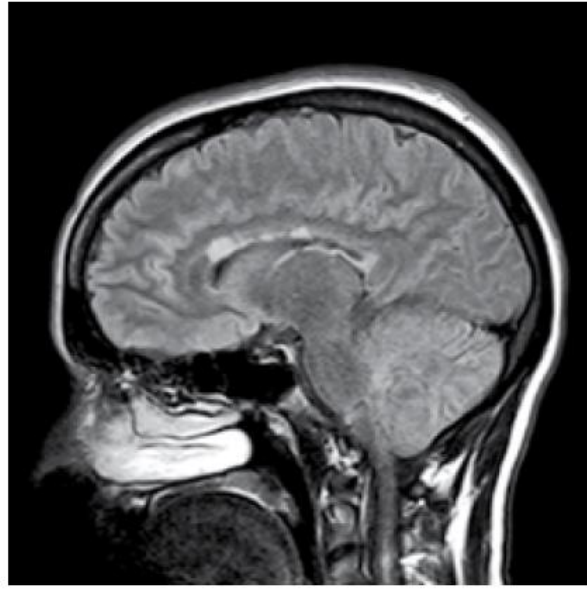


Medial

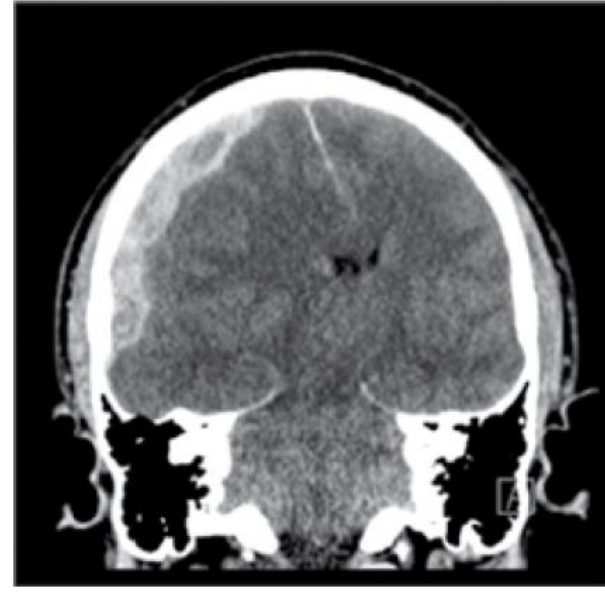



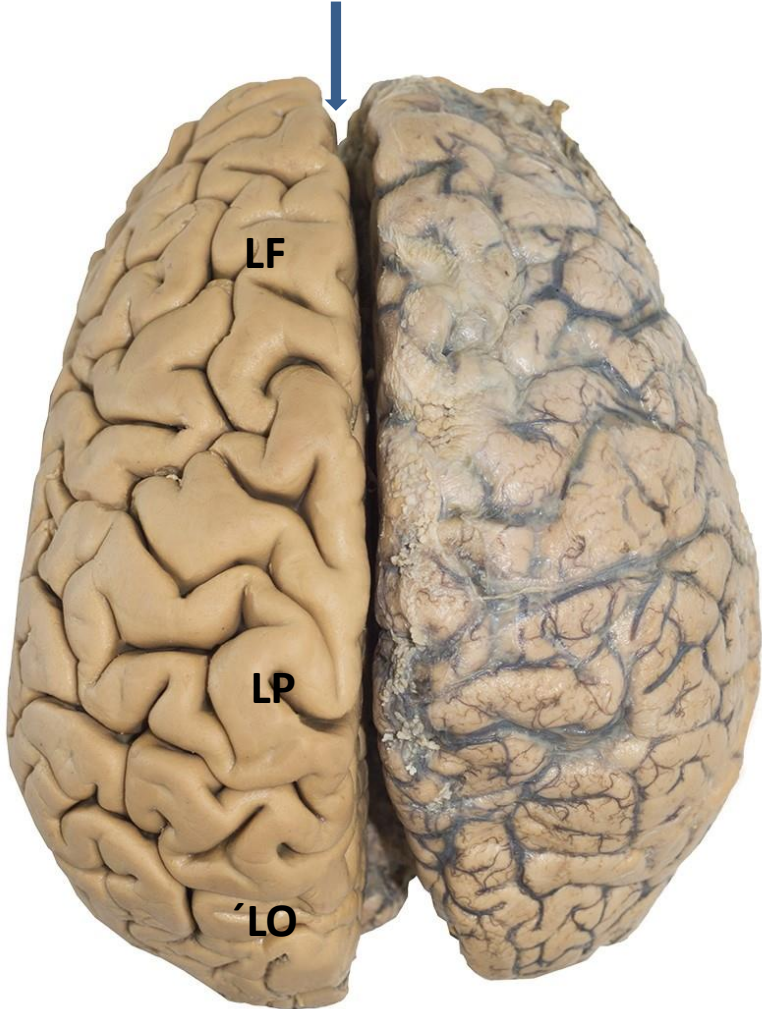
Horizontal



Sagittal



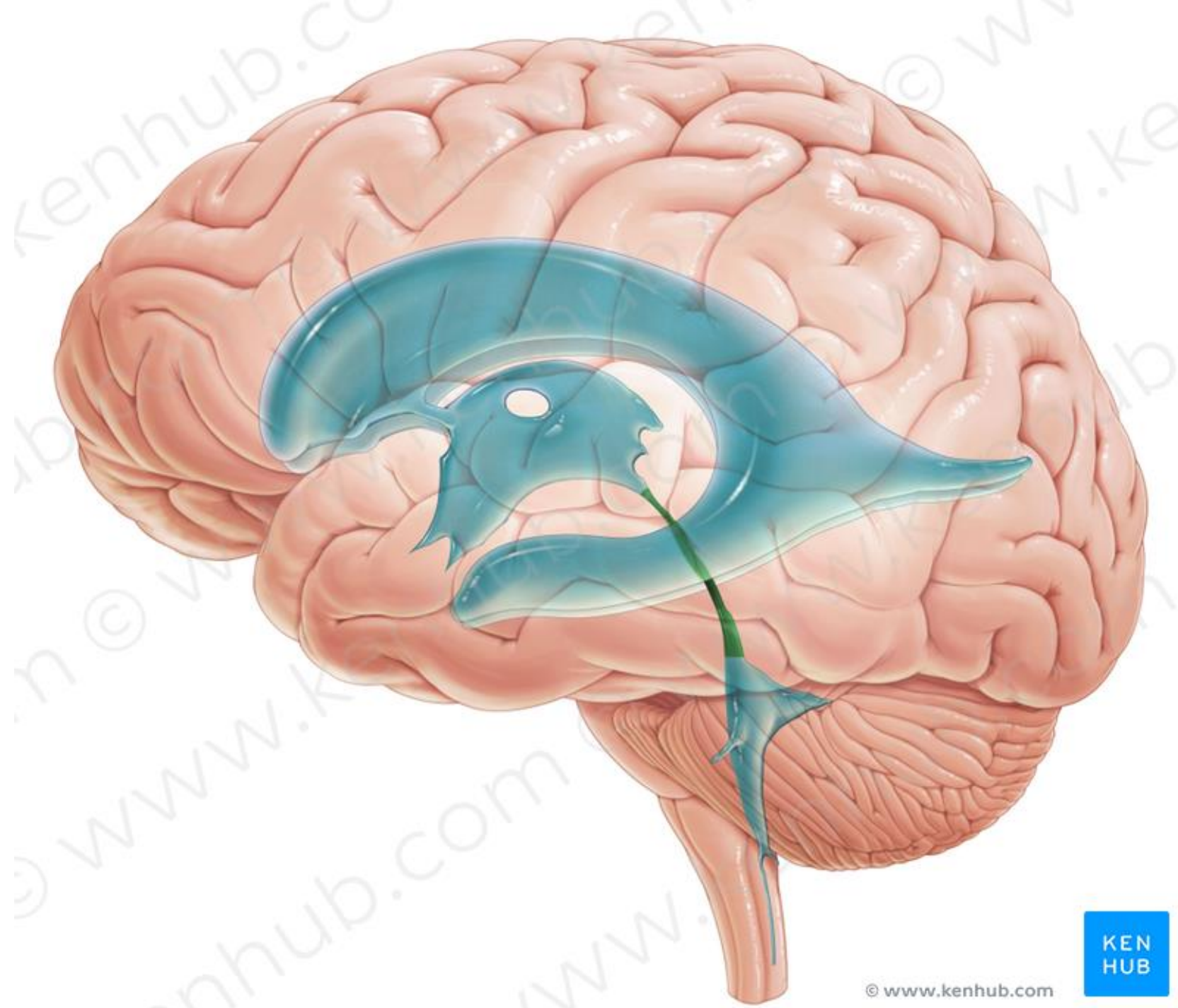
Frontal

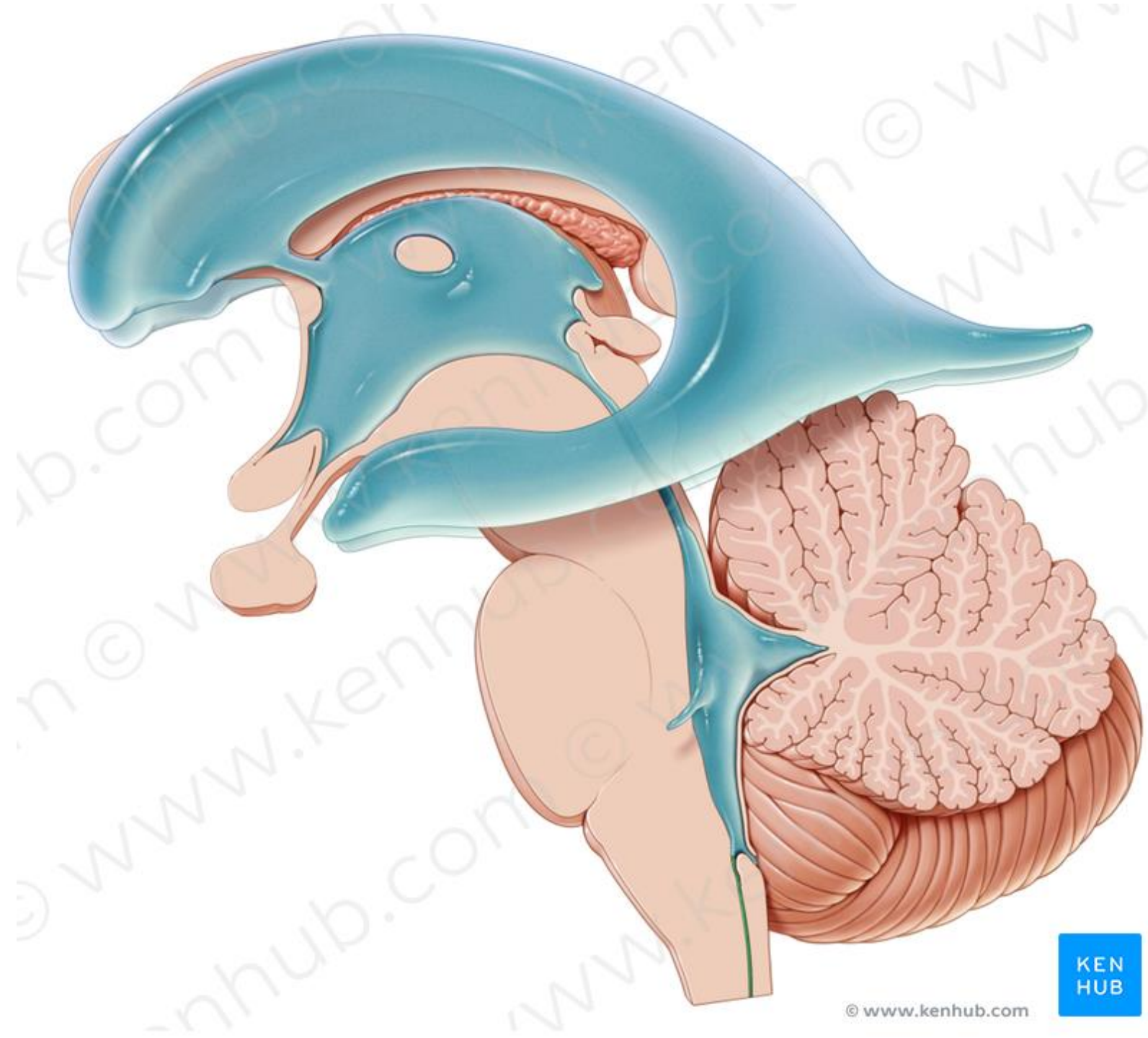


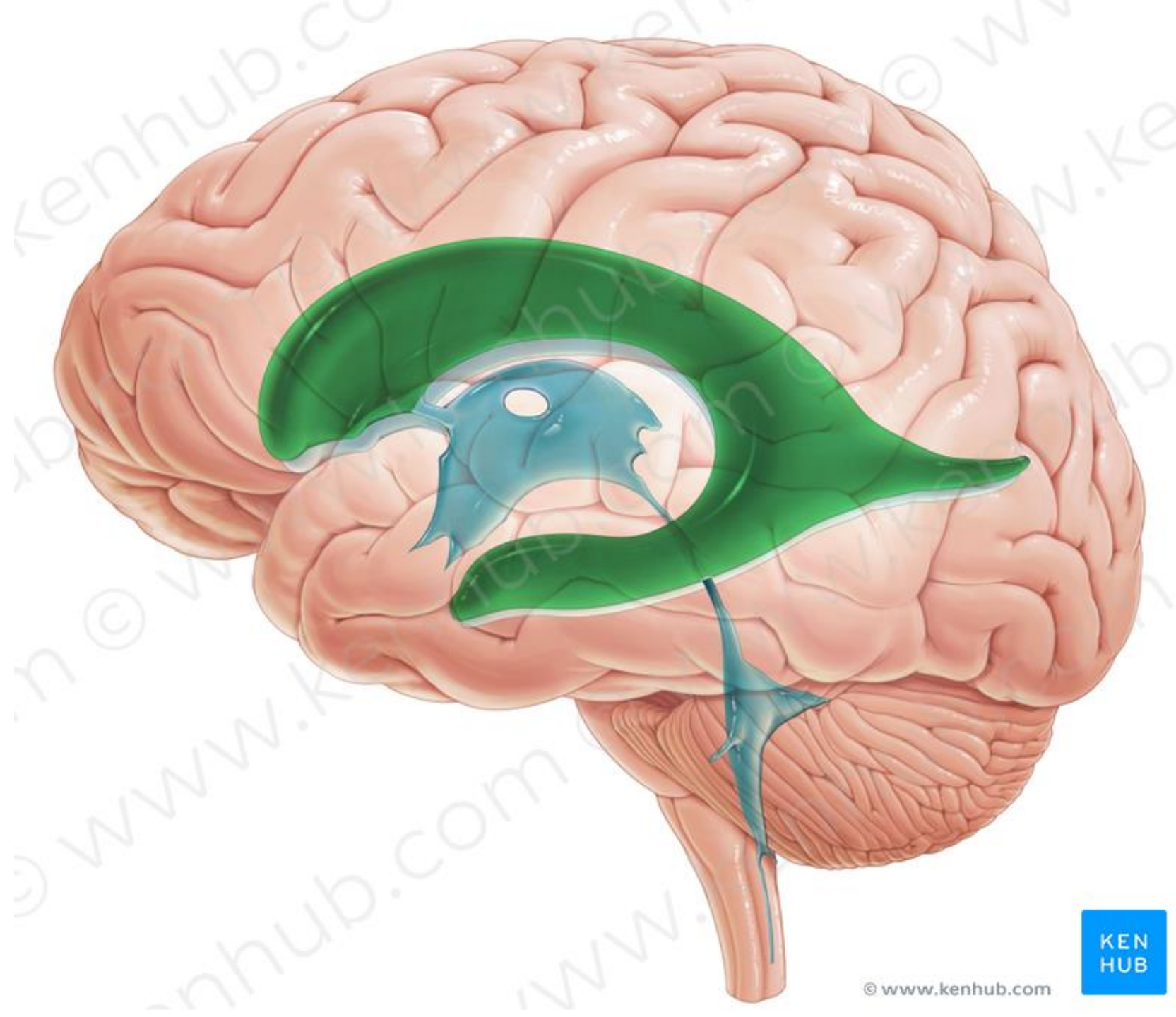
LF

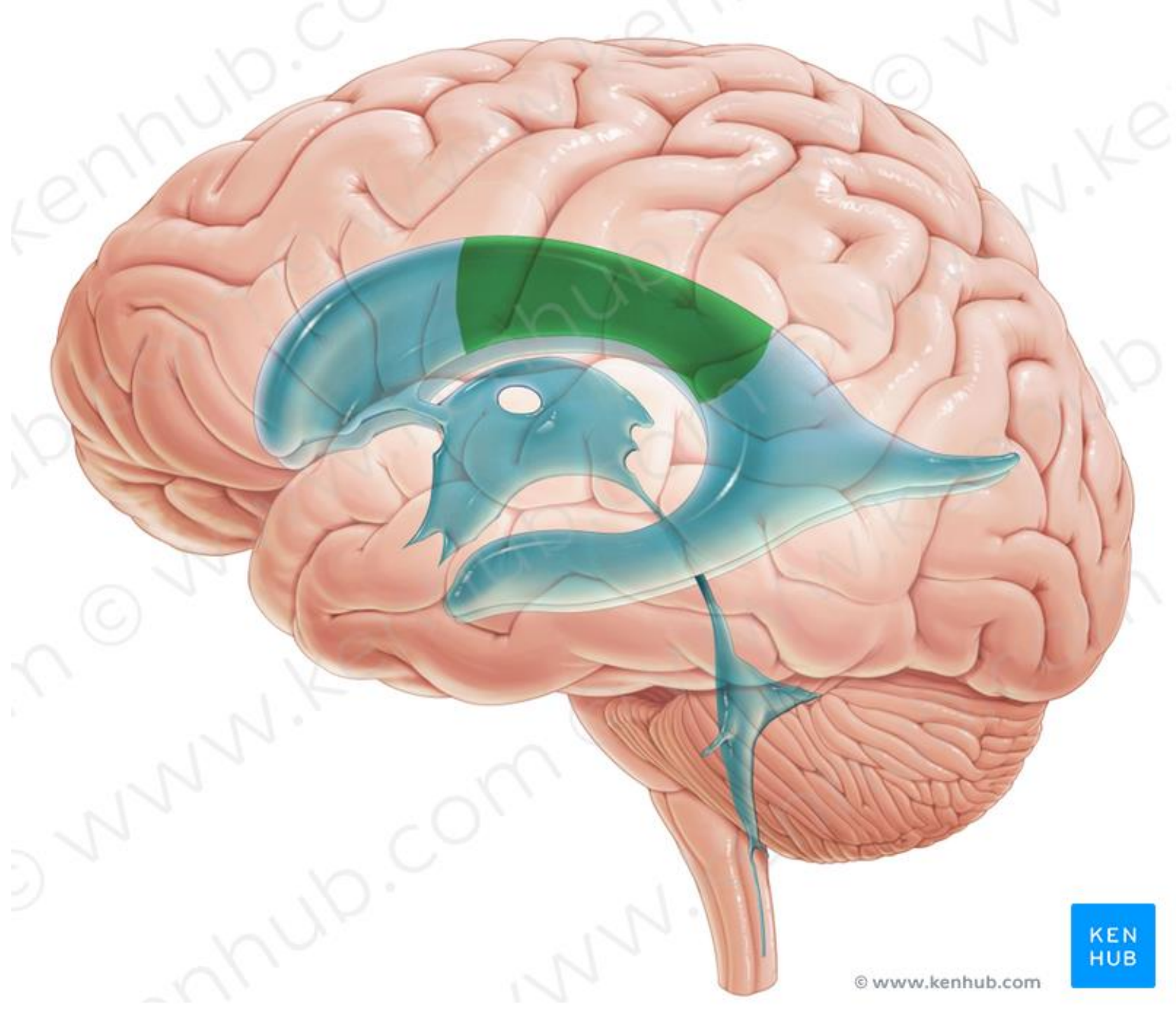
LP

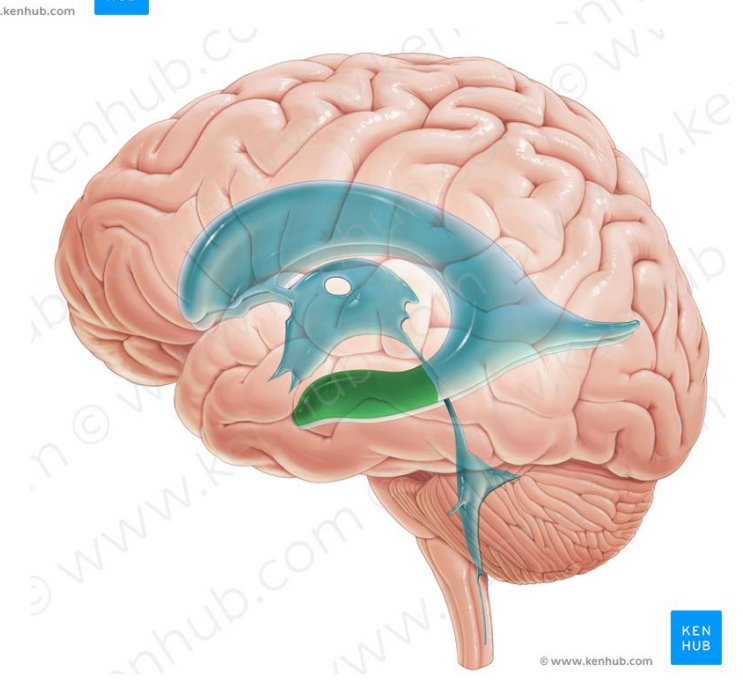
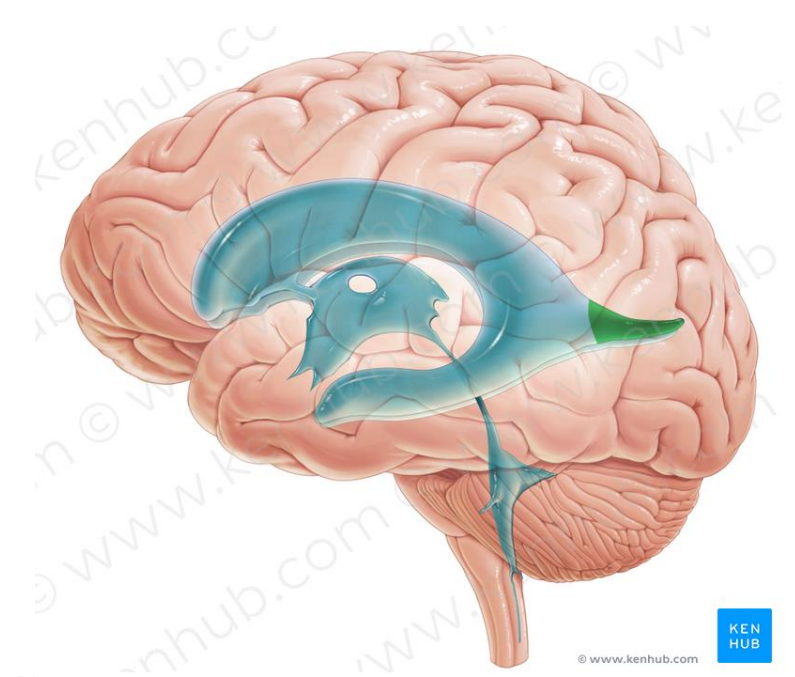
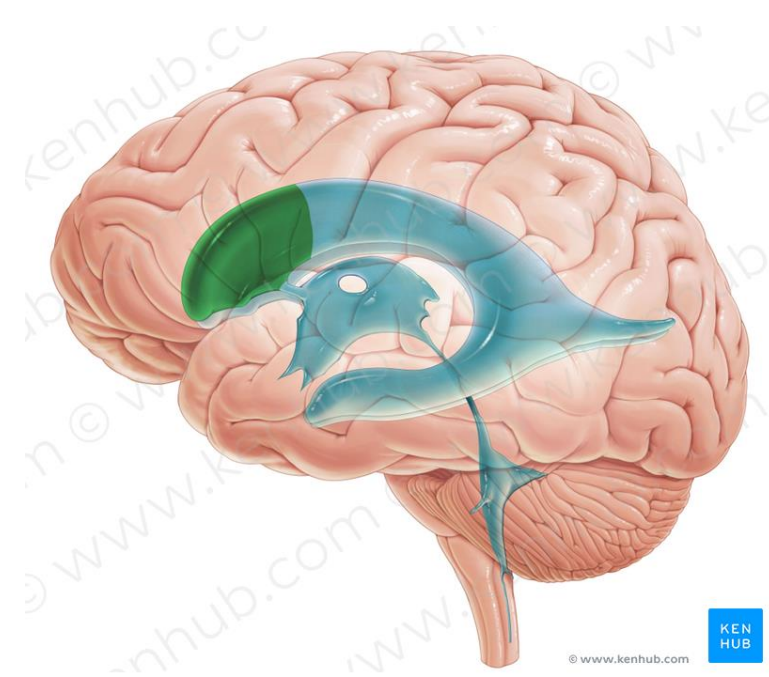
LO

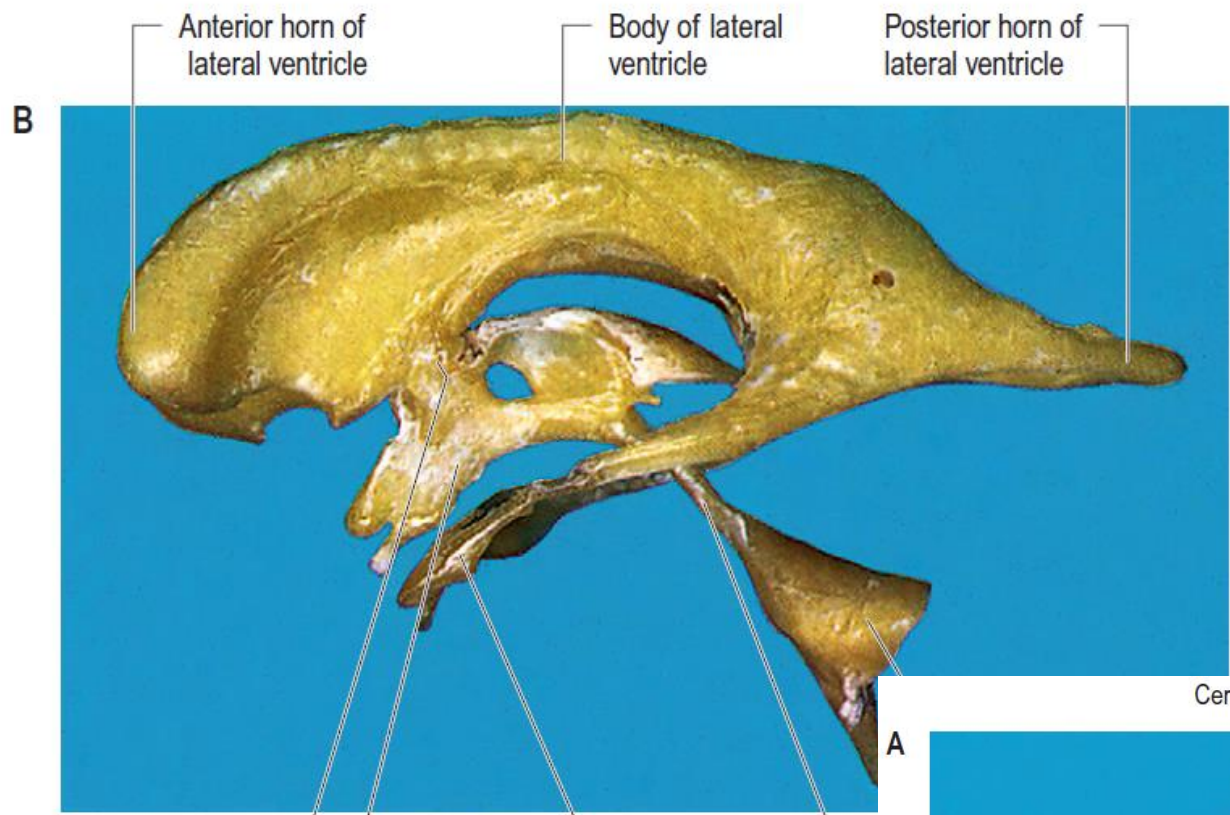








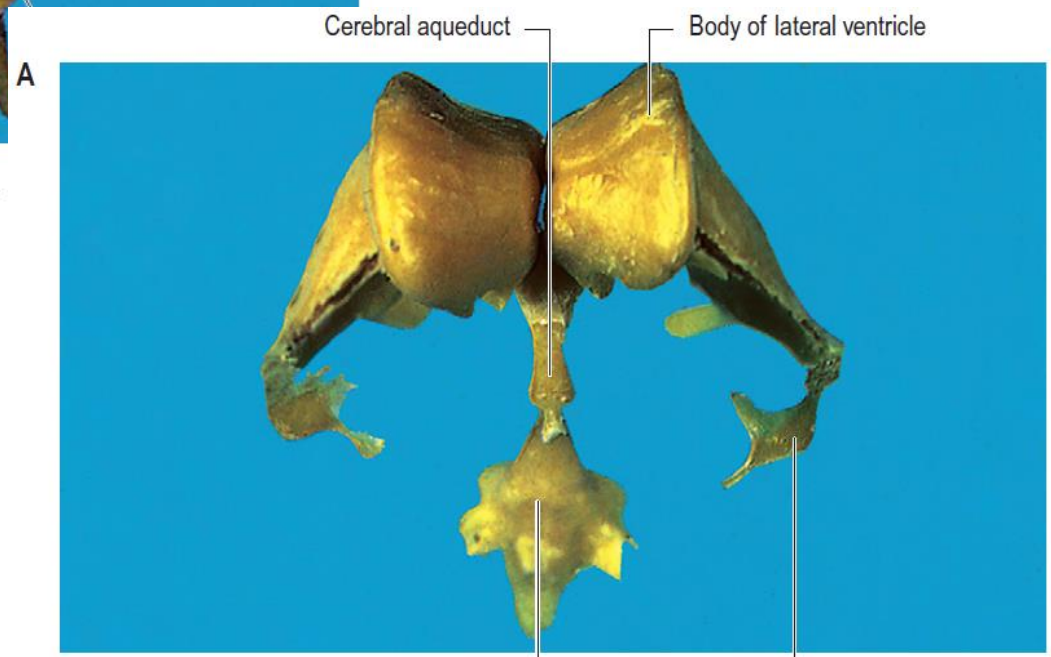




Interventricular foramen

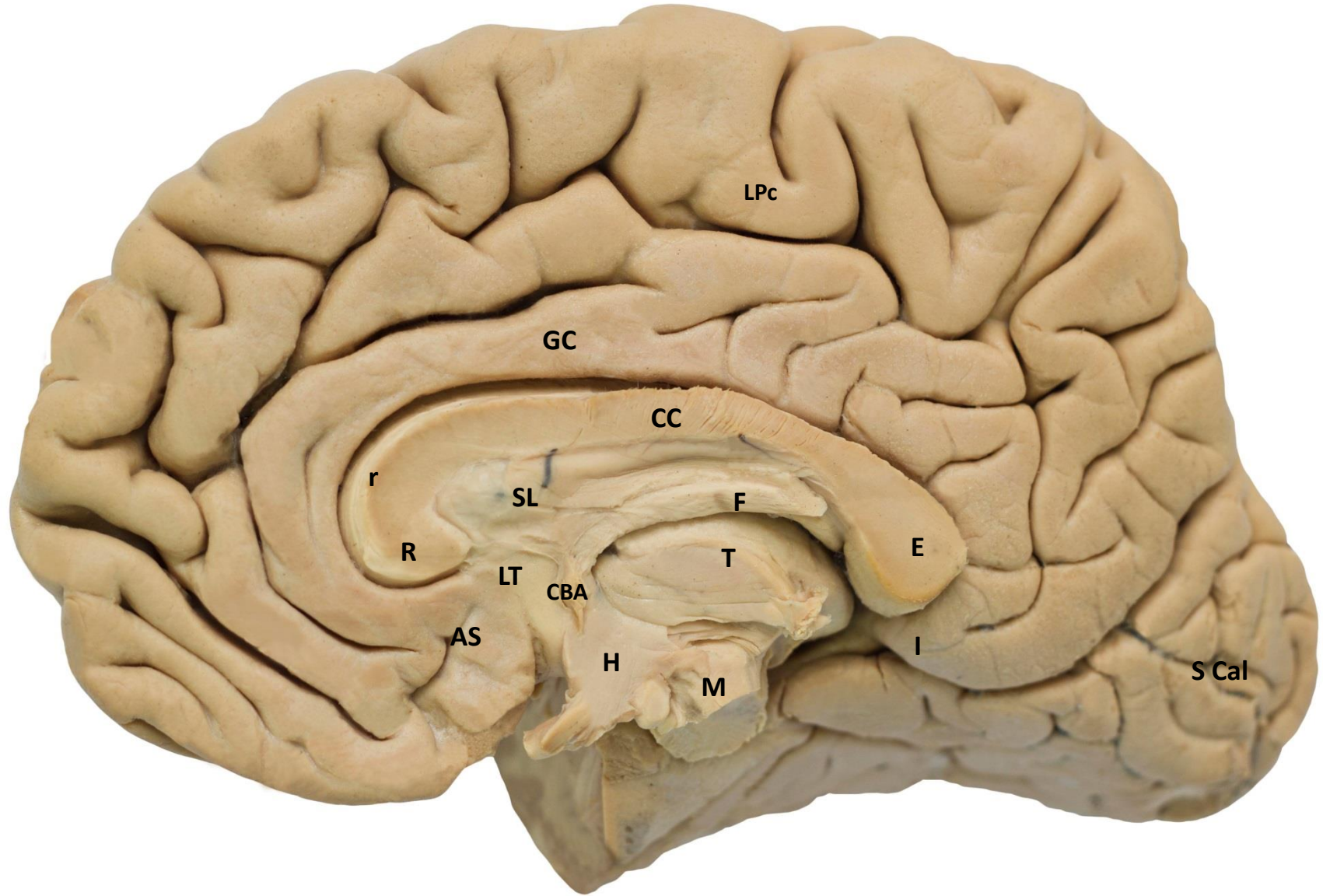
Third ventricle

Inferior horn of lateral ventricle



Fourth ventricle

Inferior horn of lateral ventricle



LPc

GC

CC

r

SL

F

R

T

E

LT

CBA

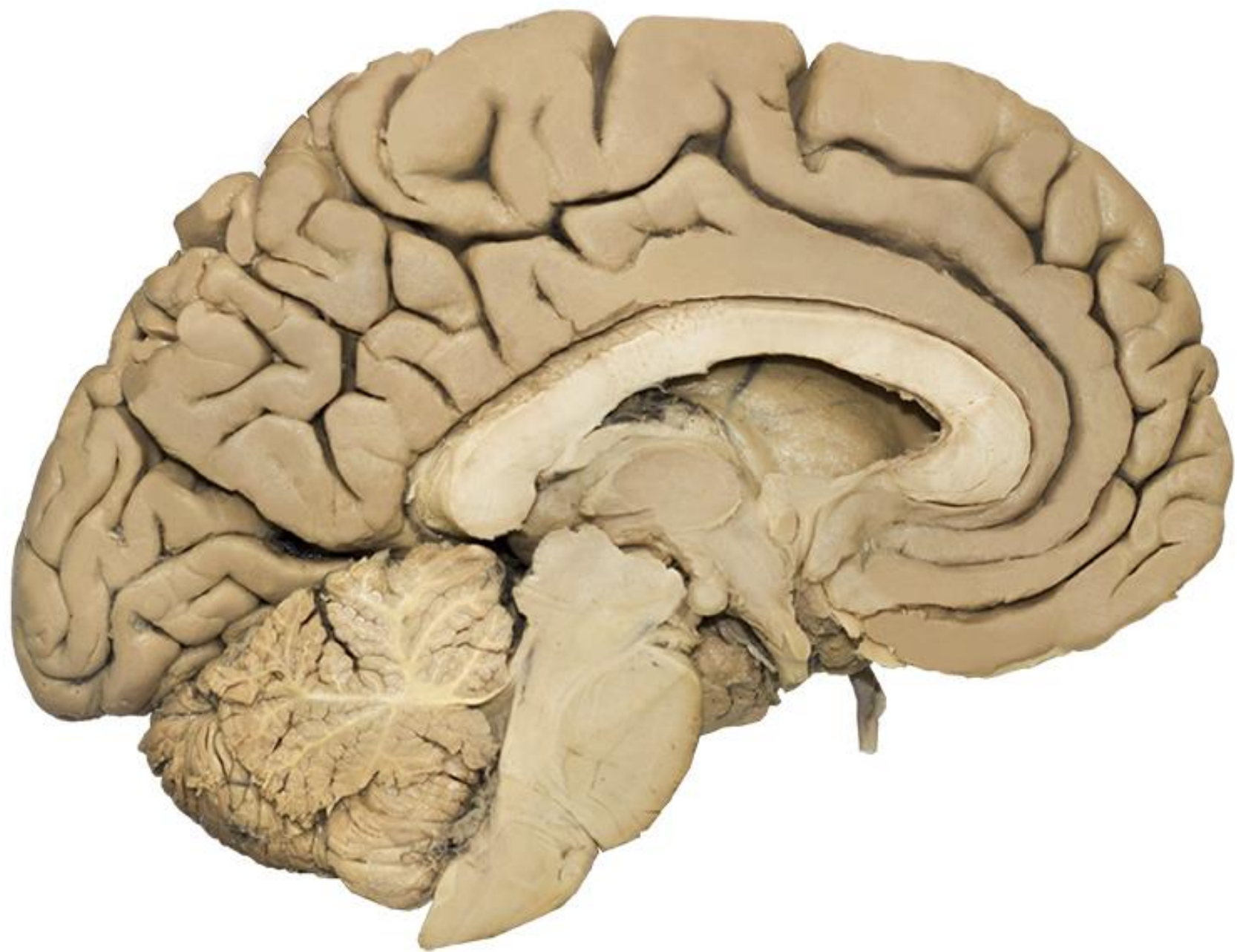AS

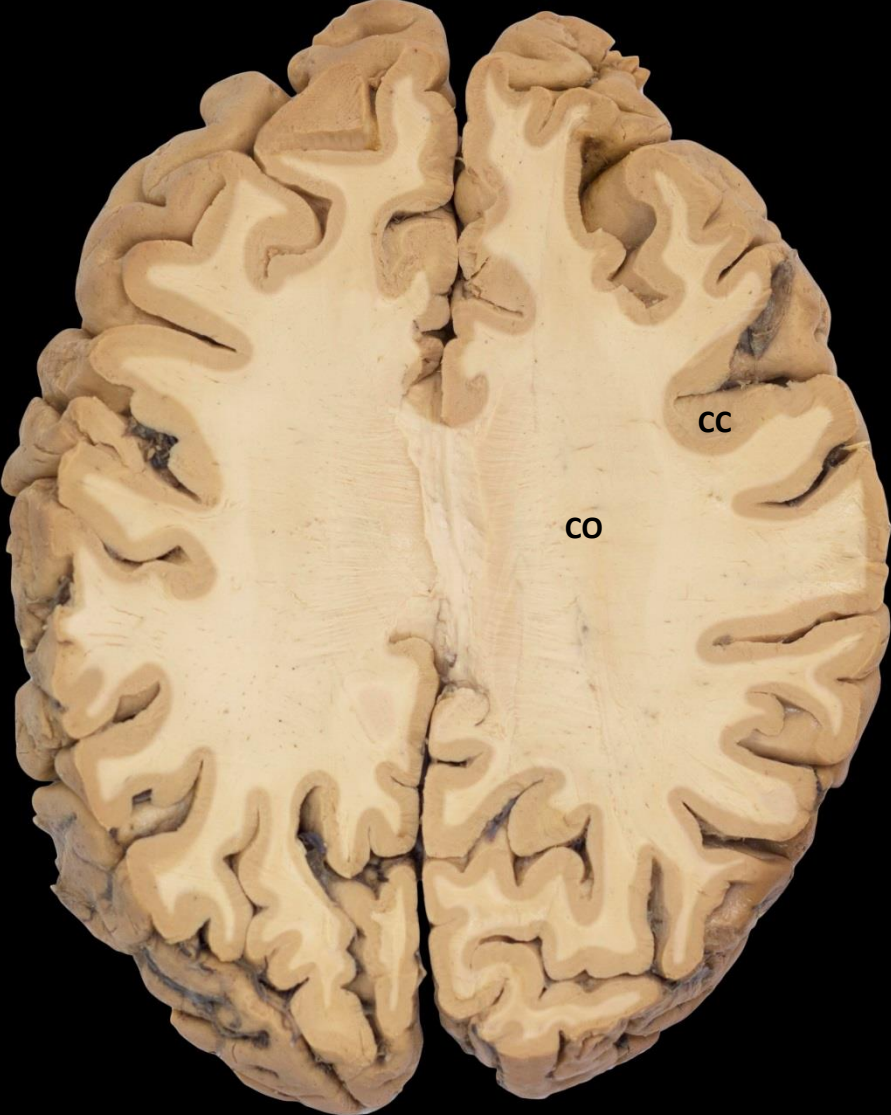
H

M

I

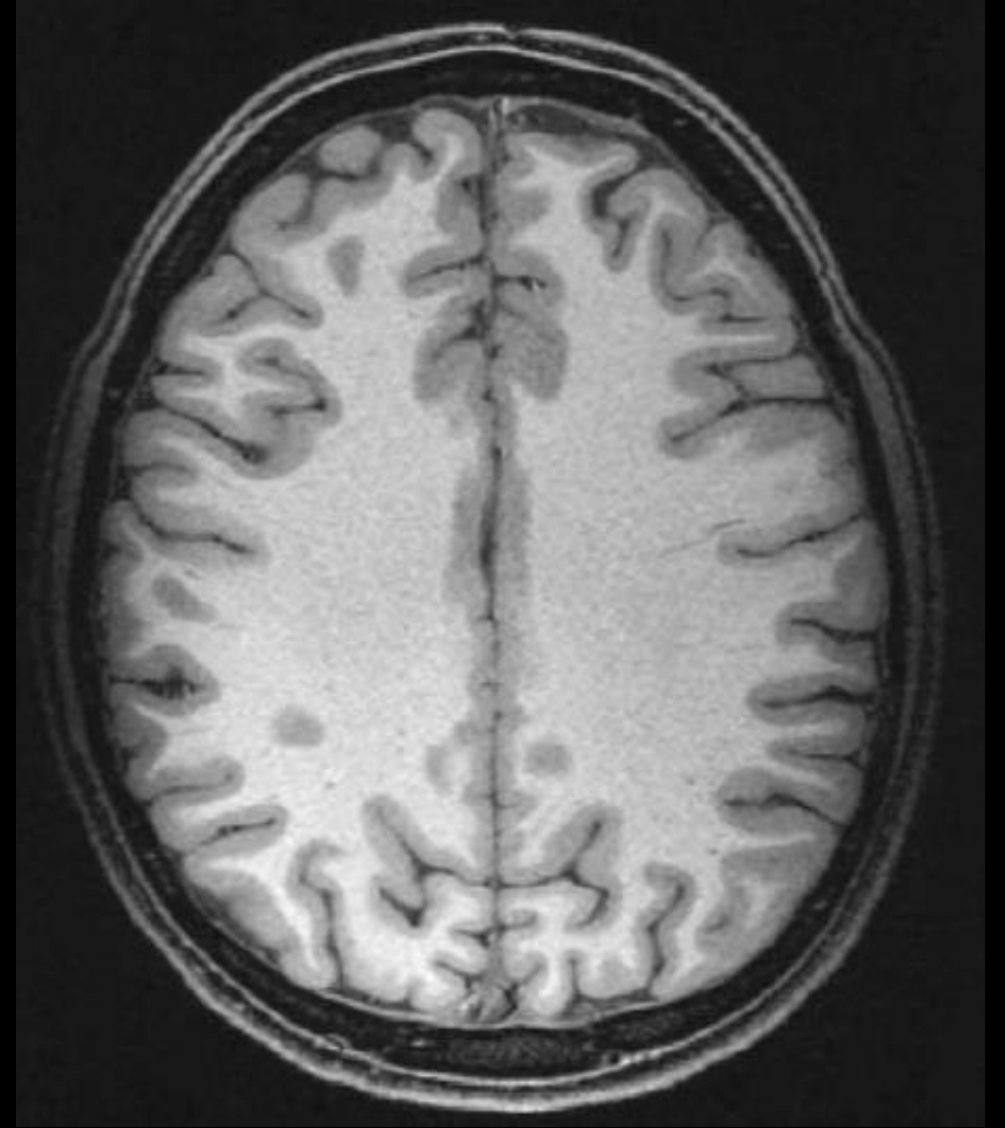
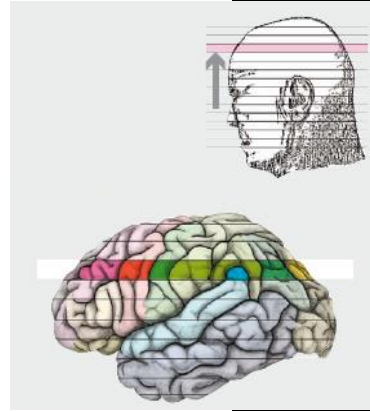
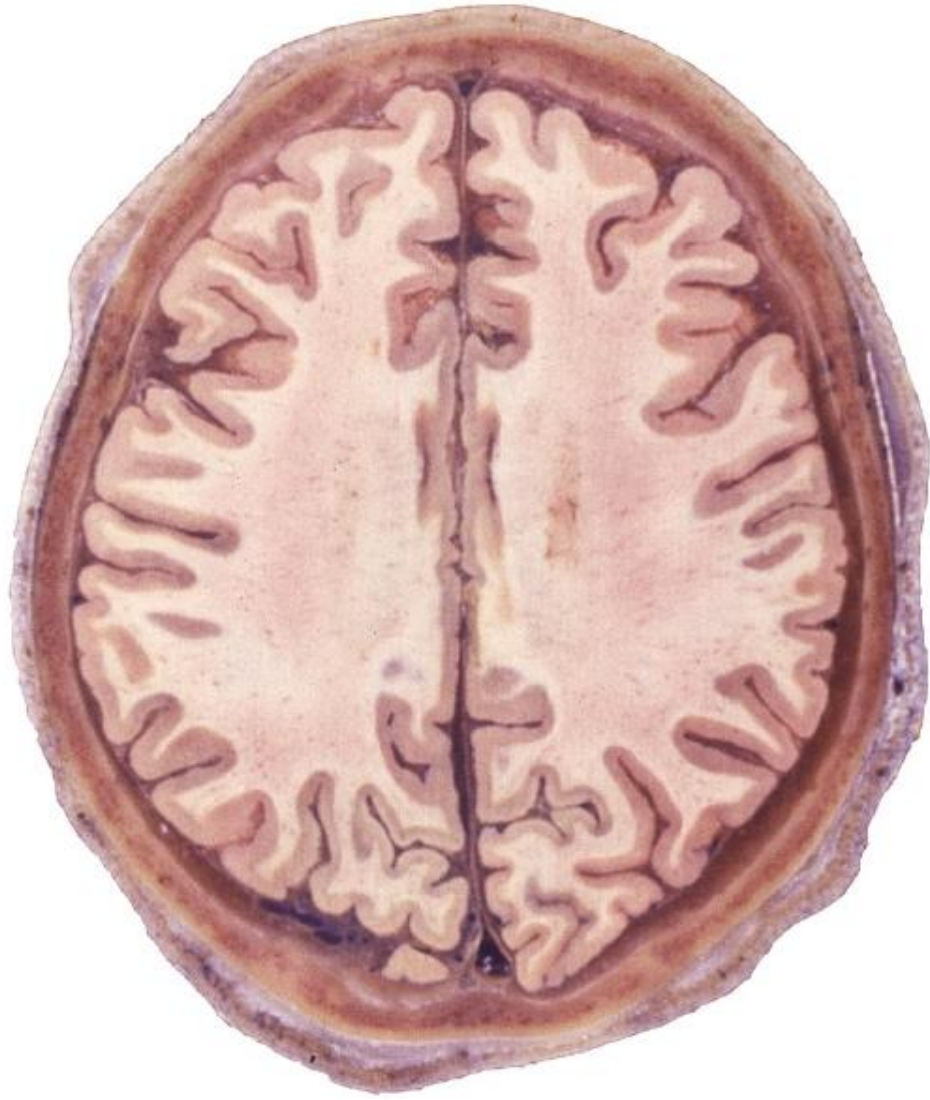
S Cal

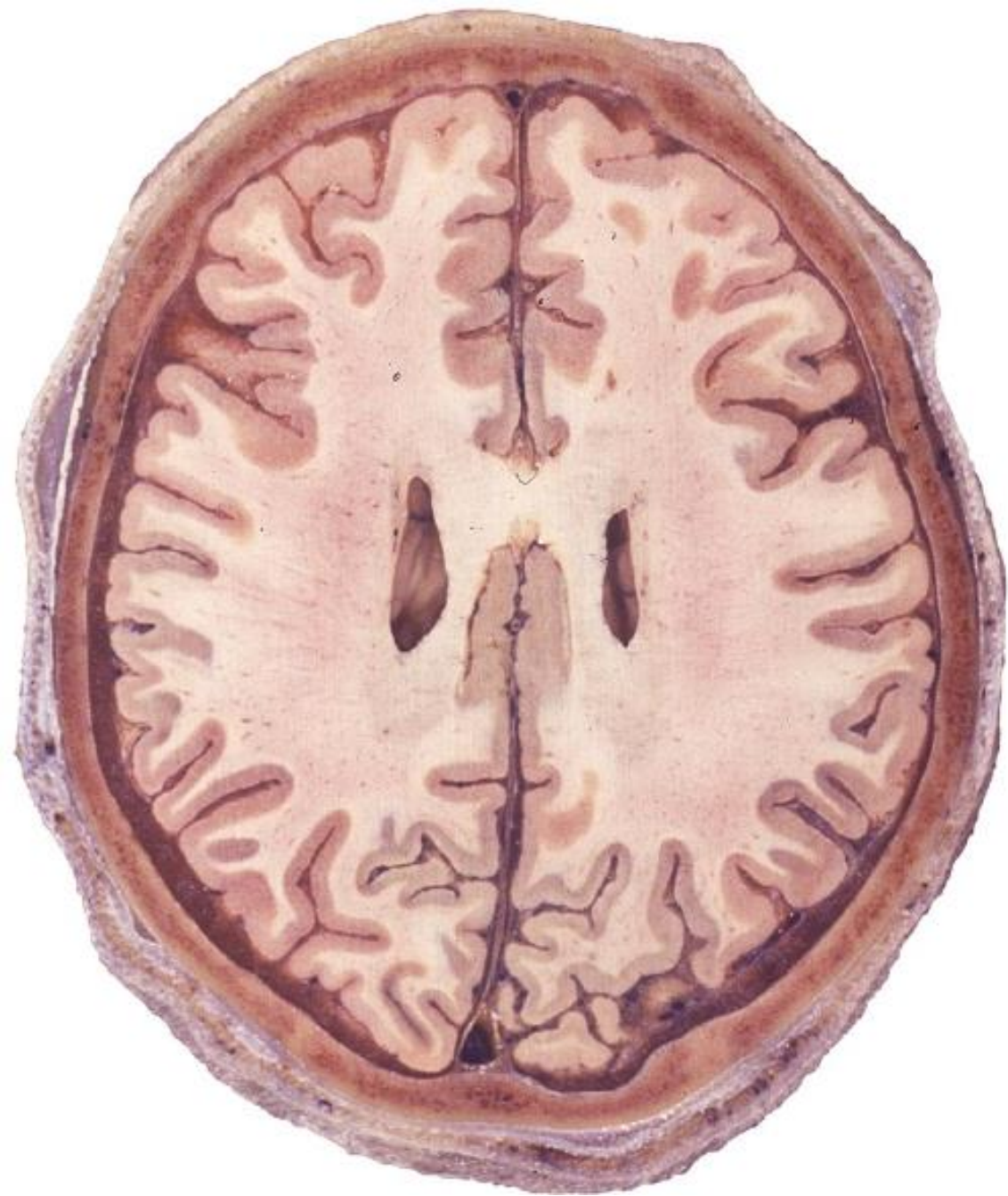


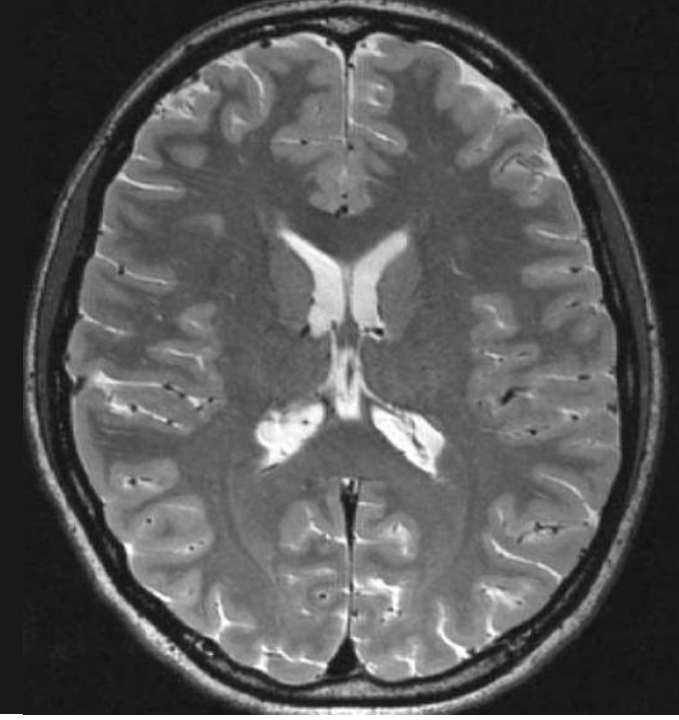
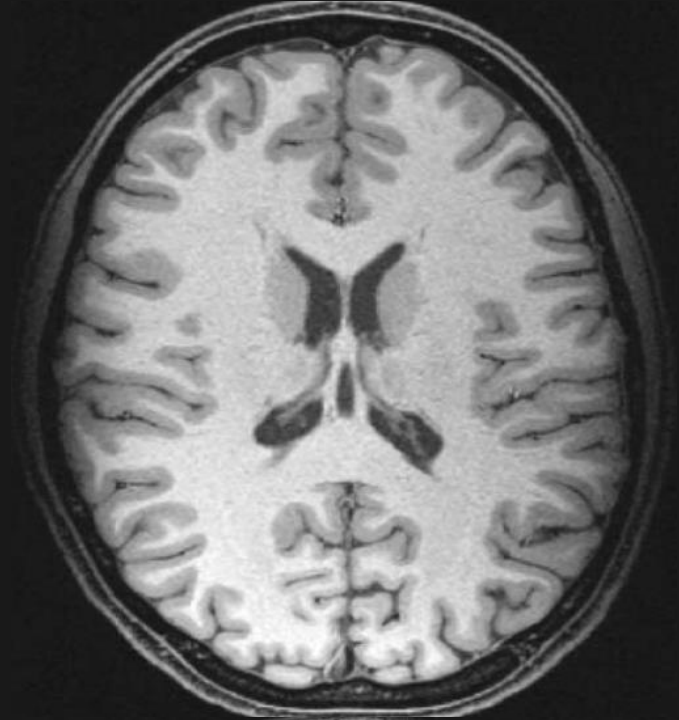
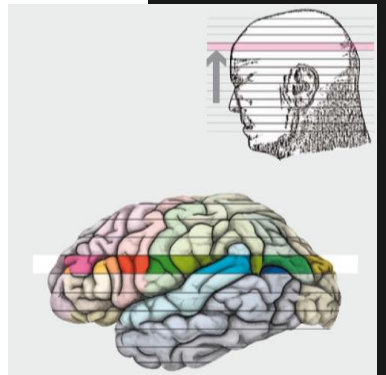
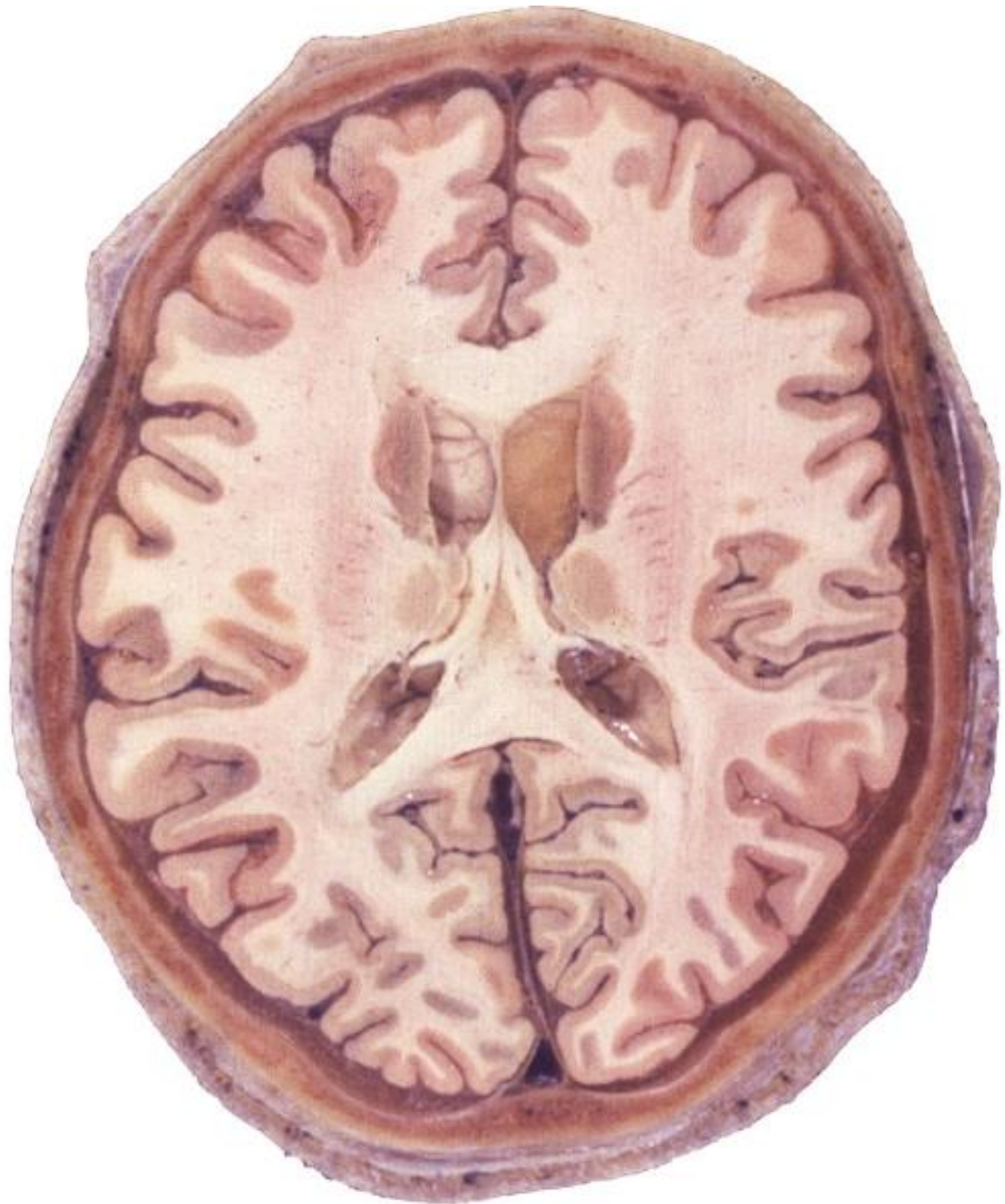


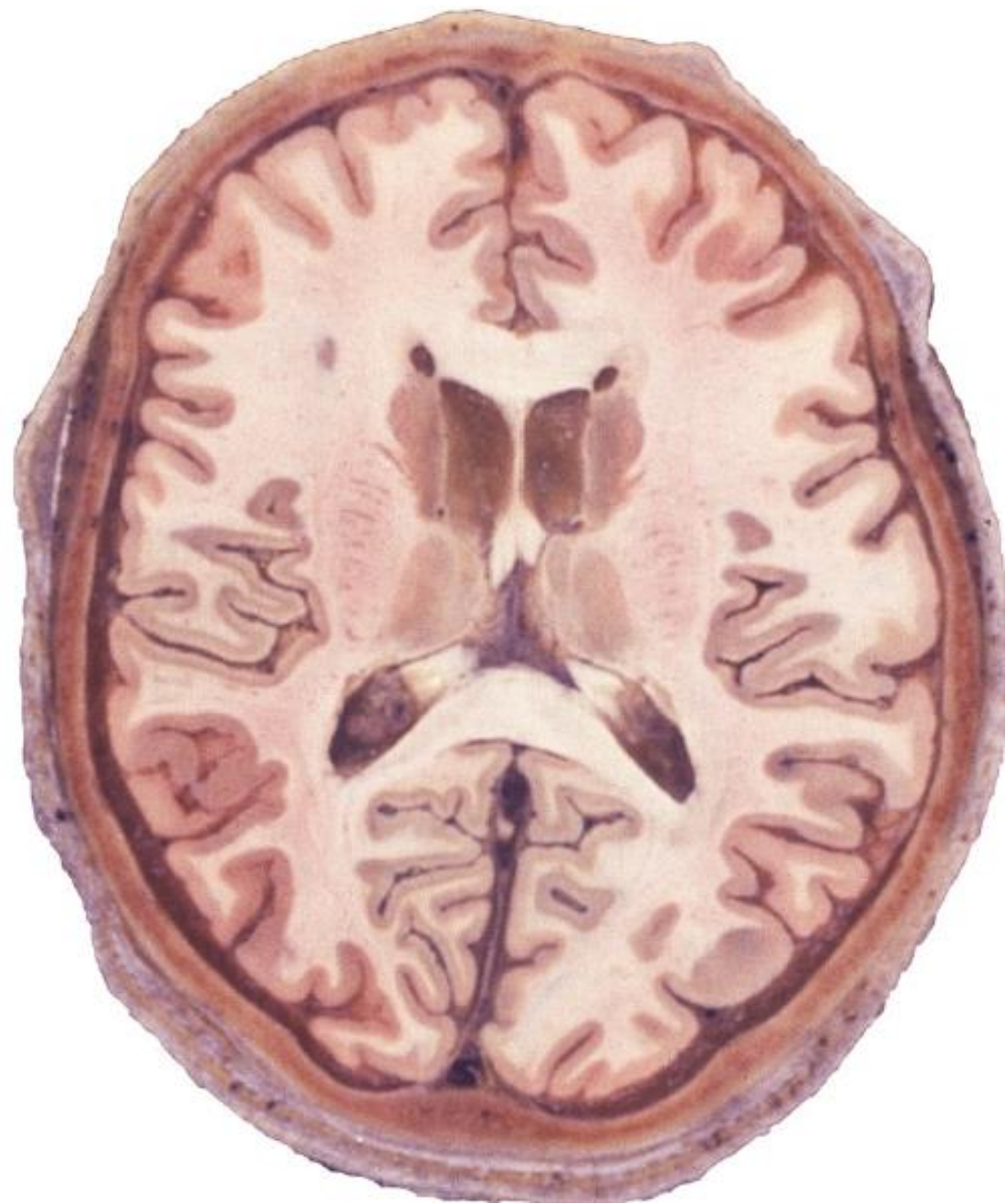cc

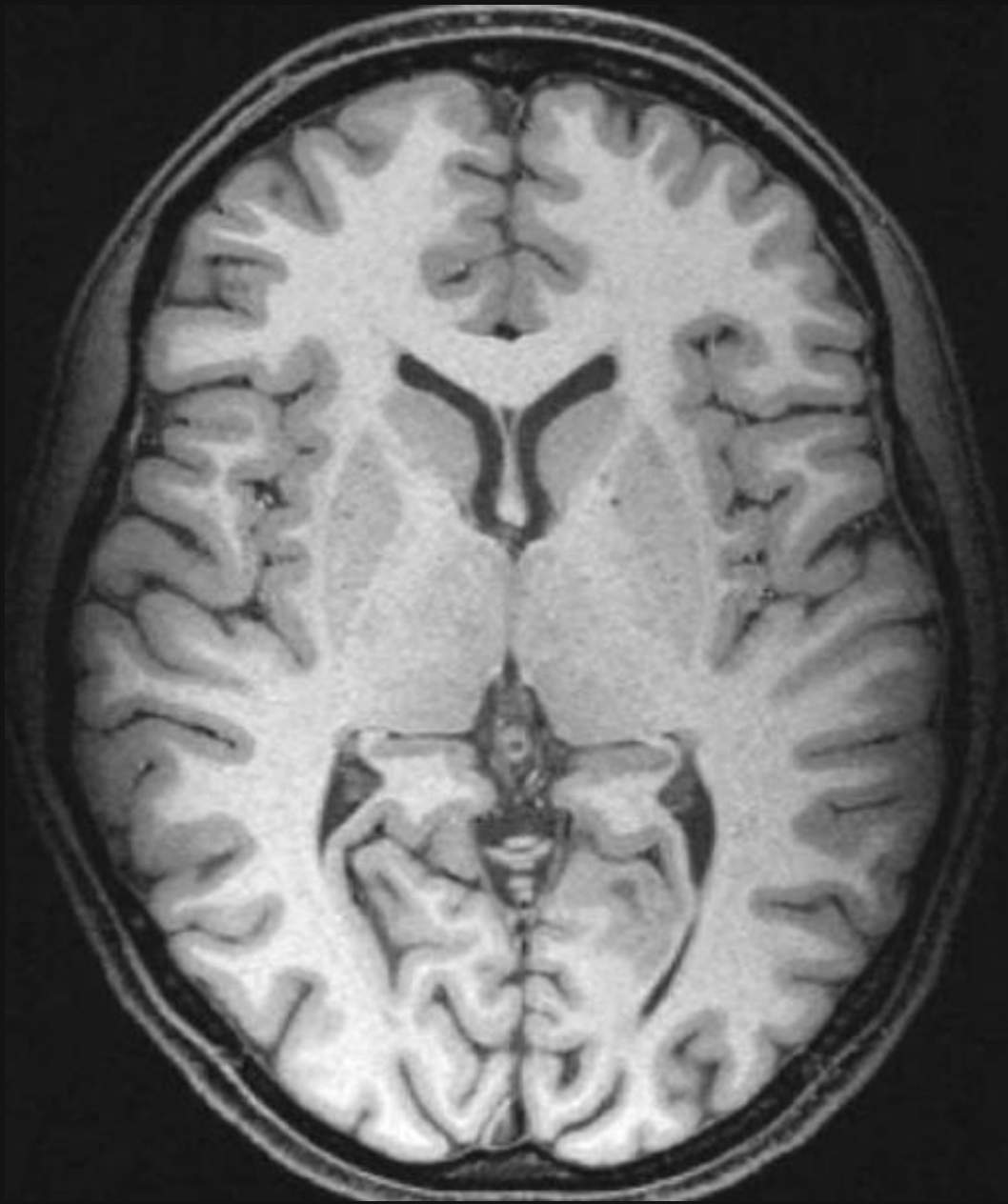
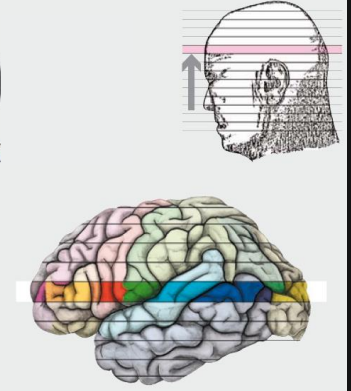
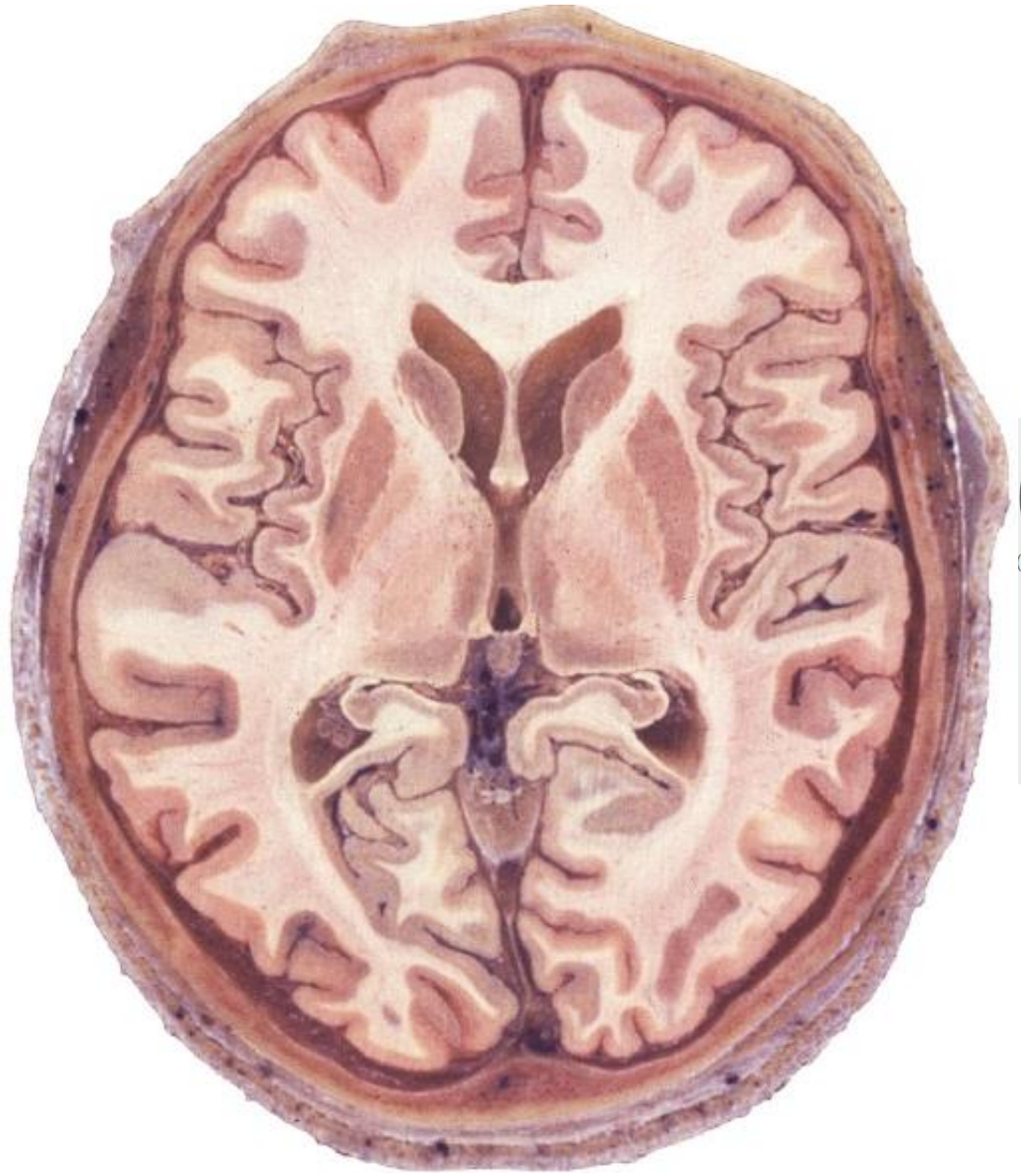
co

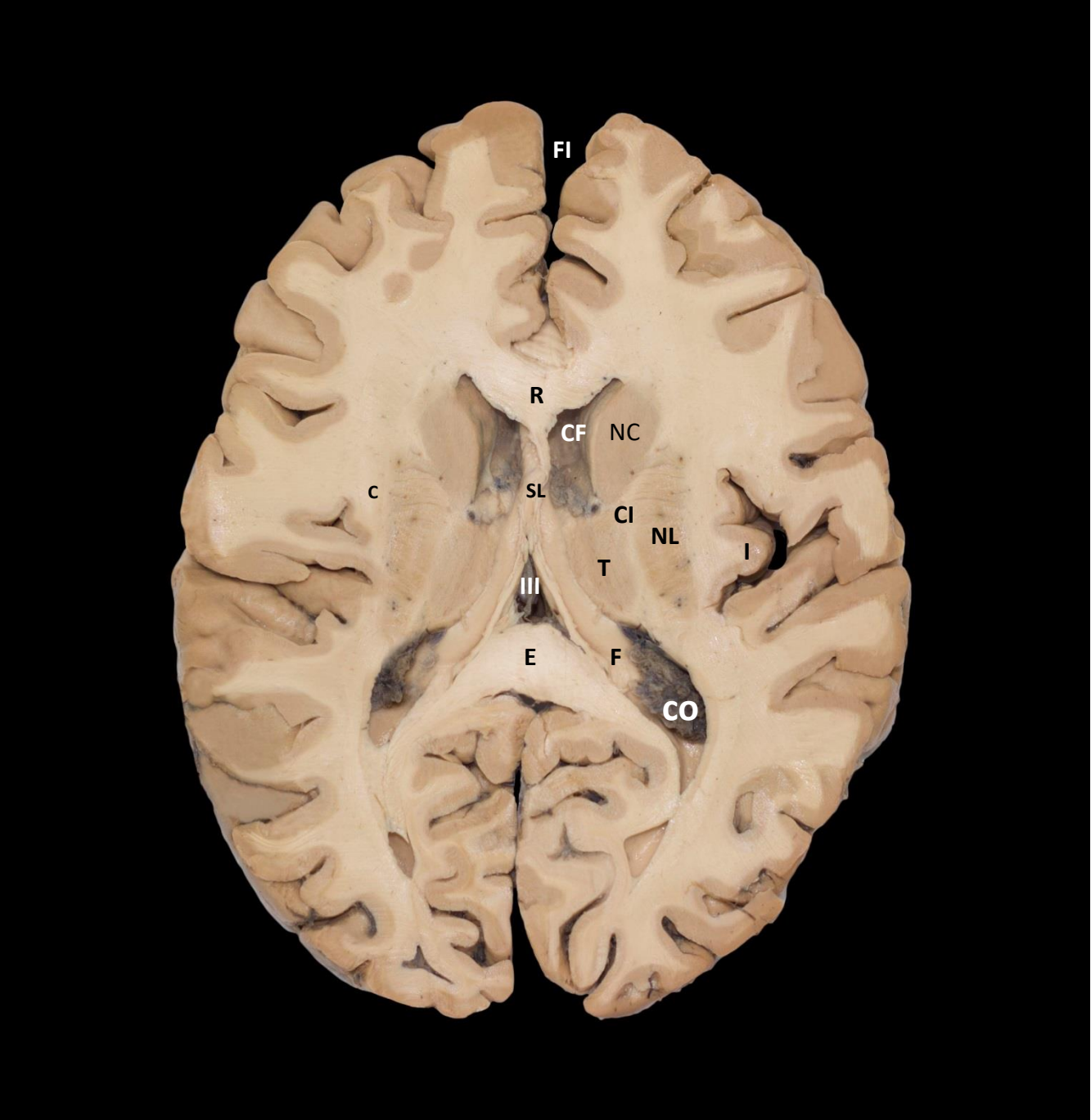

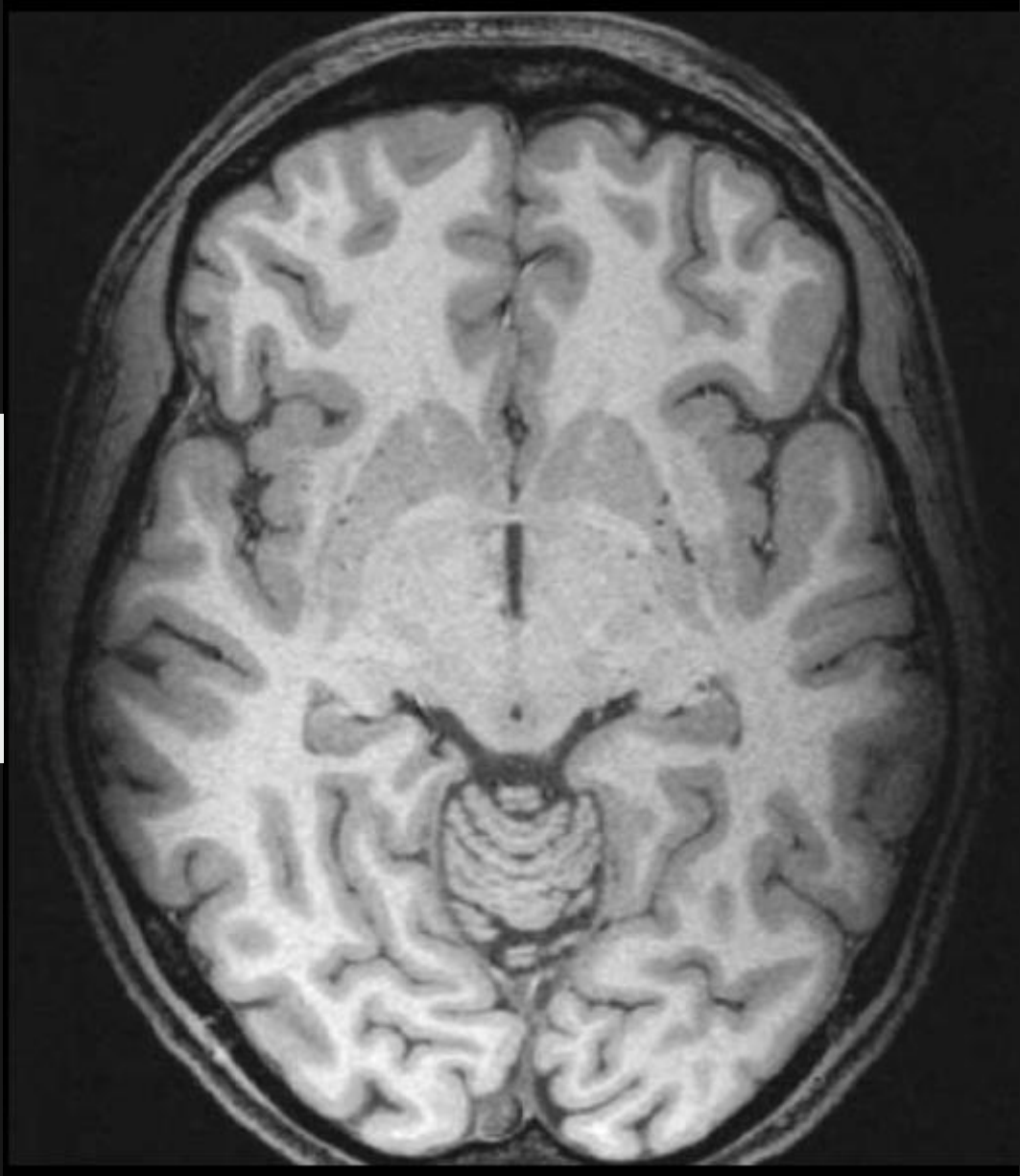
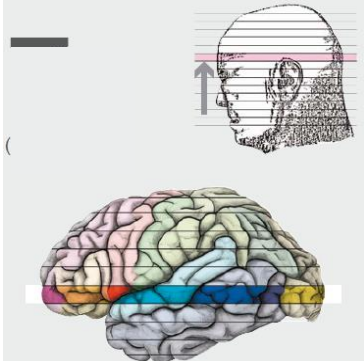
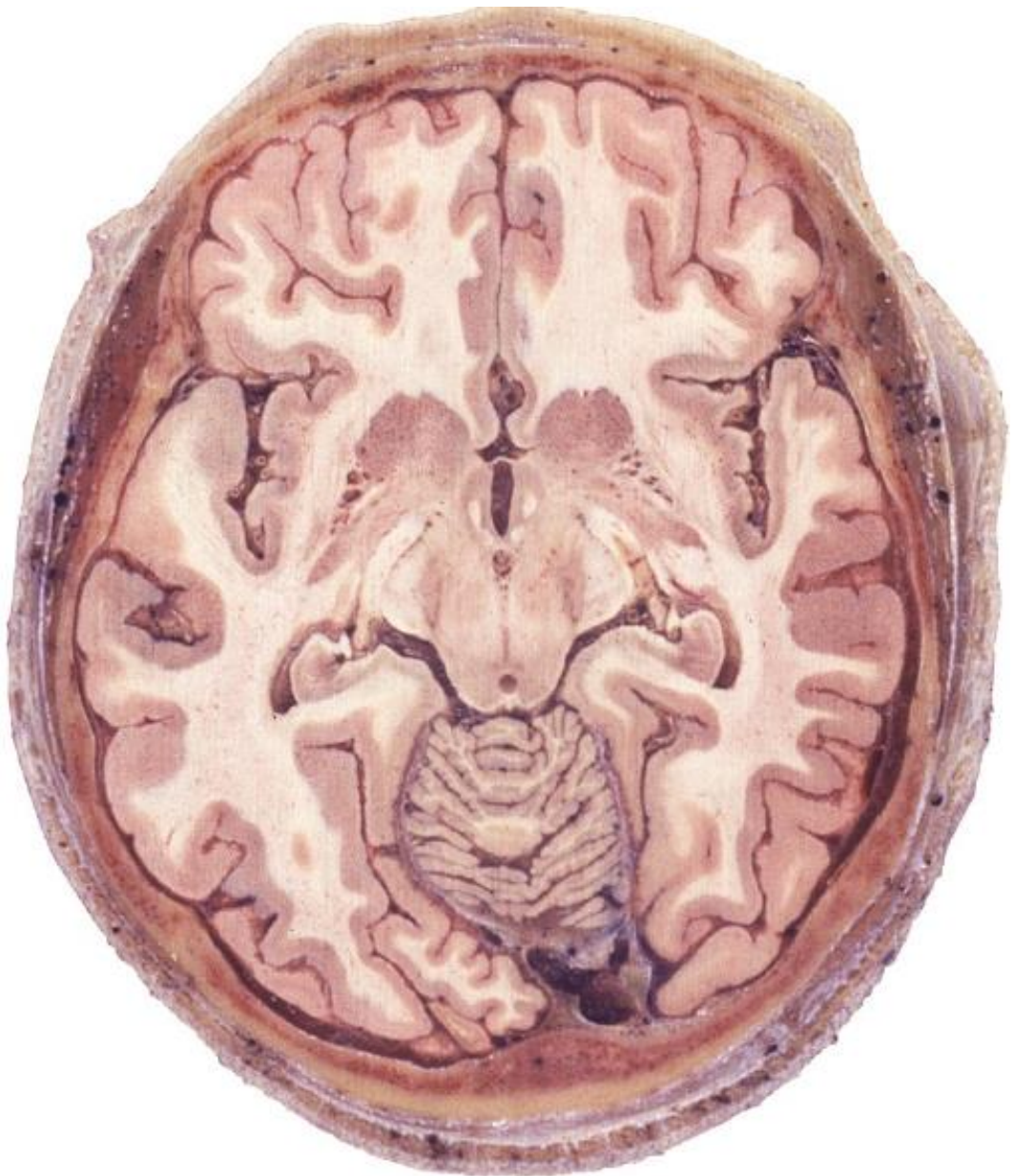


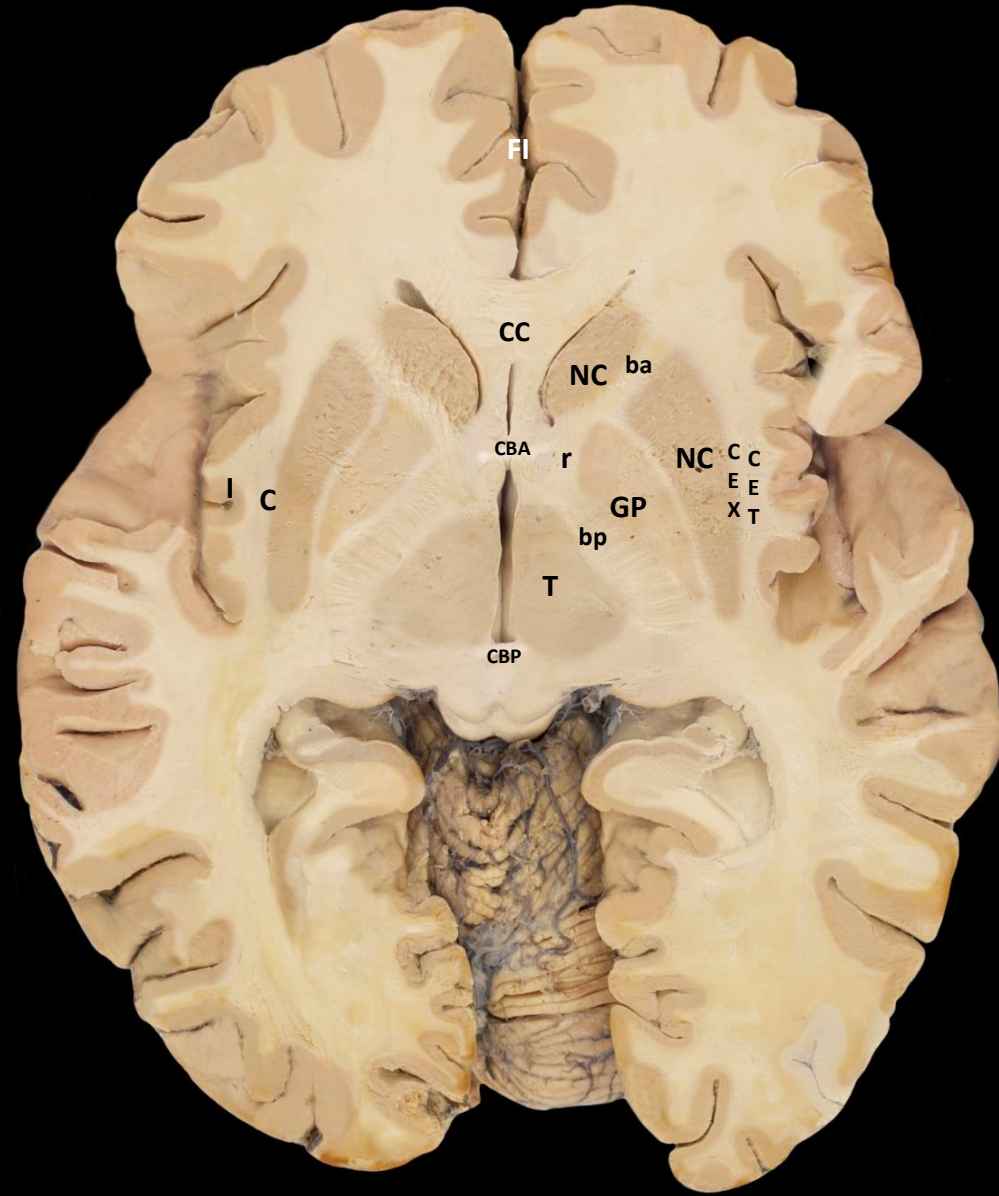












FI

CC

NC

ba

CBA

r

NC

CC

EE

XT

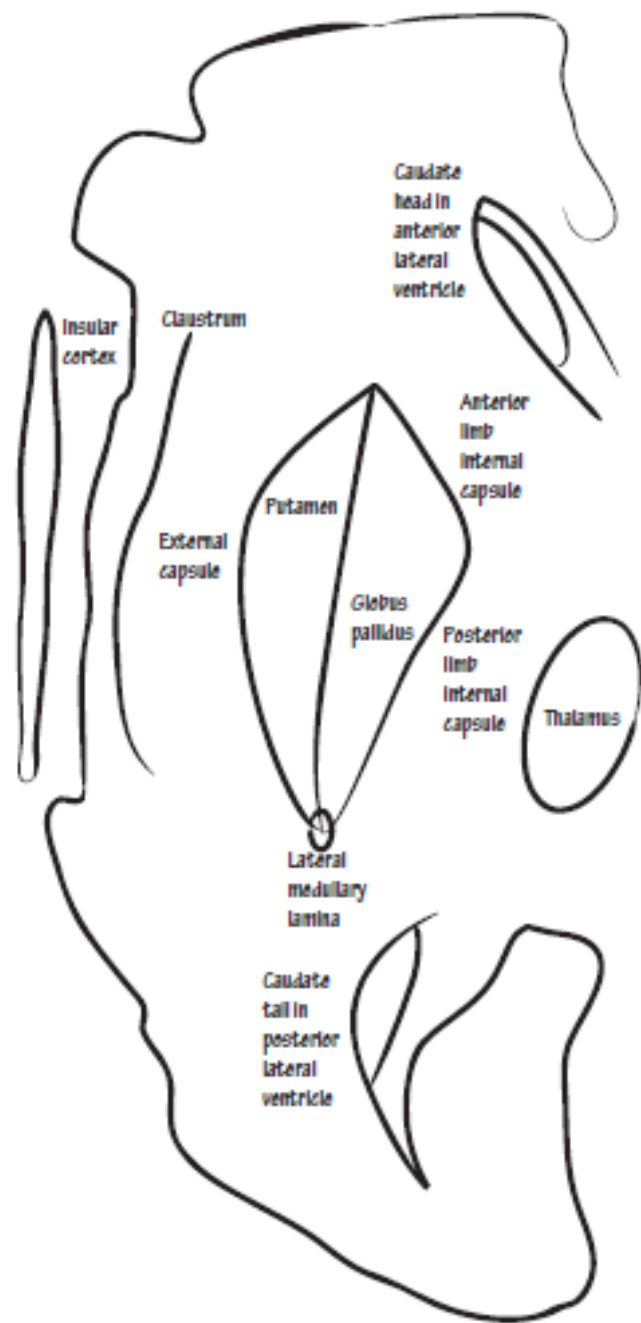
I C

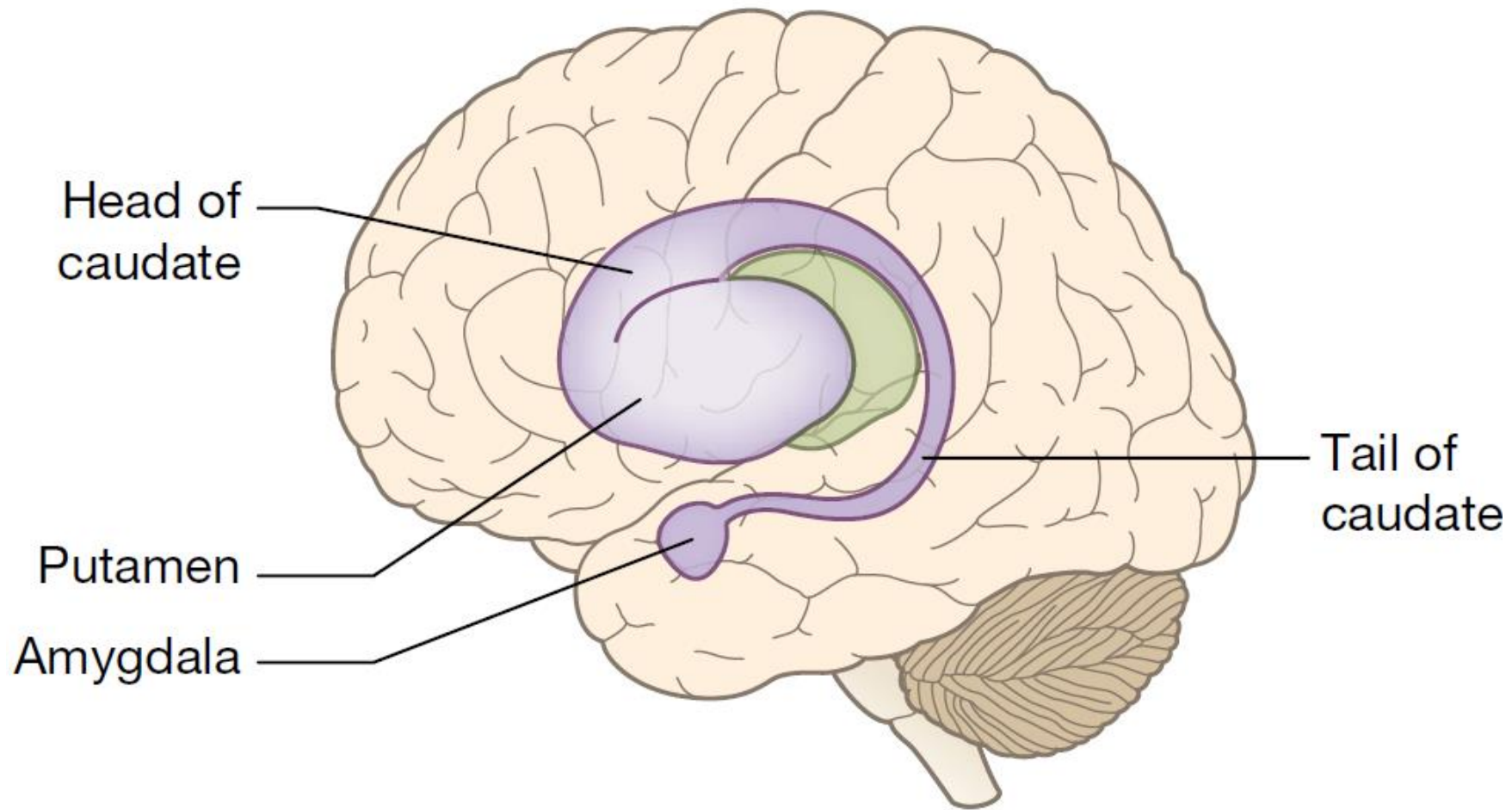
GP

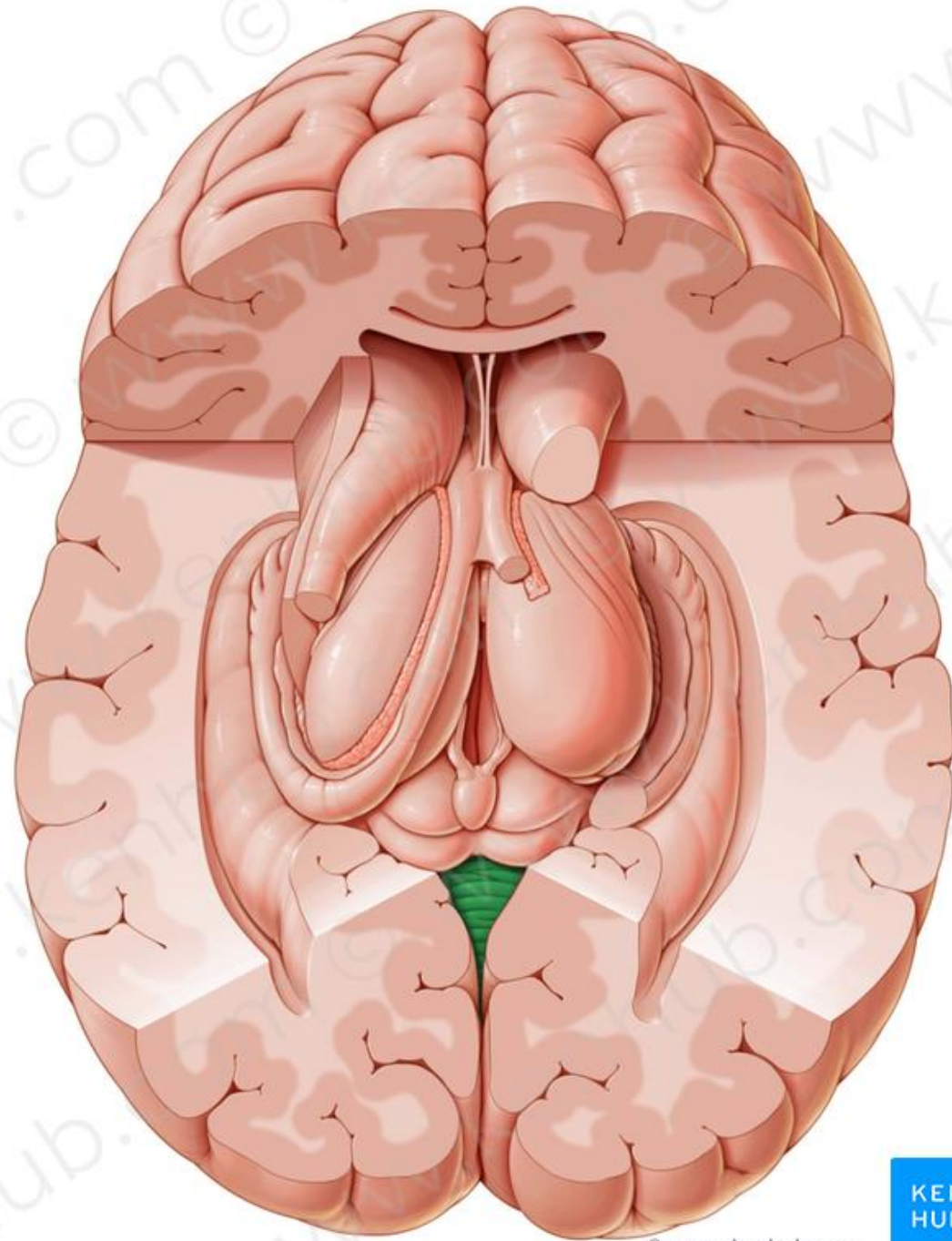
bp

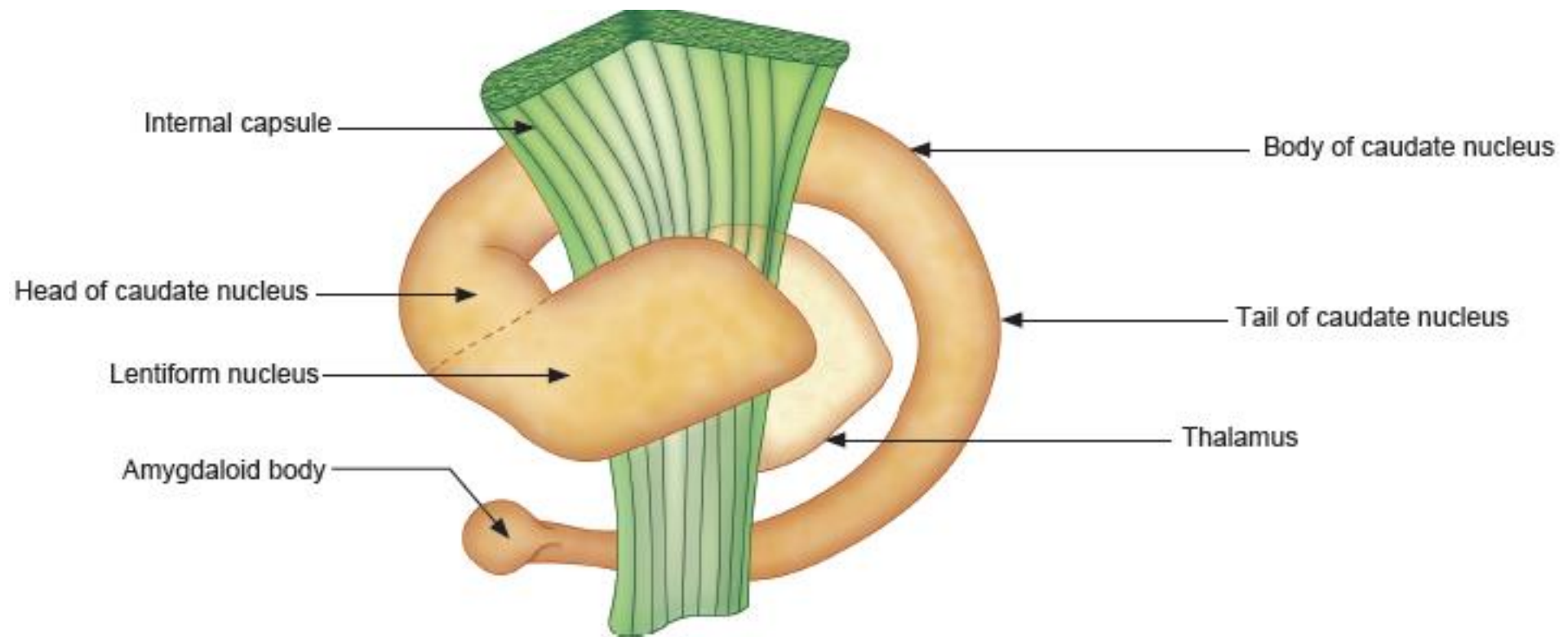
T

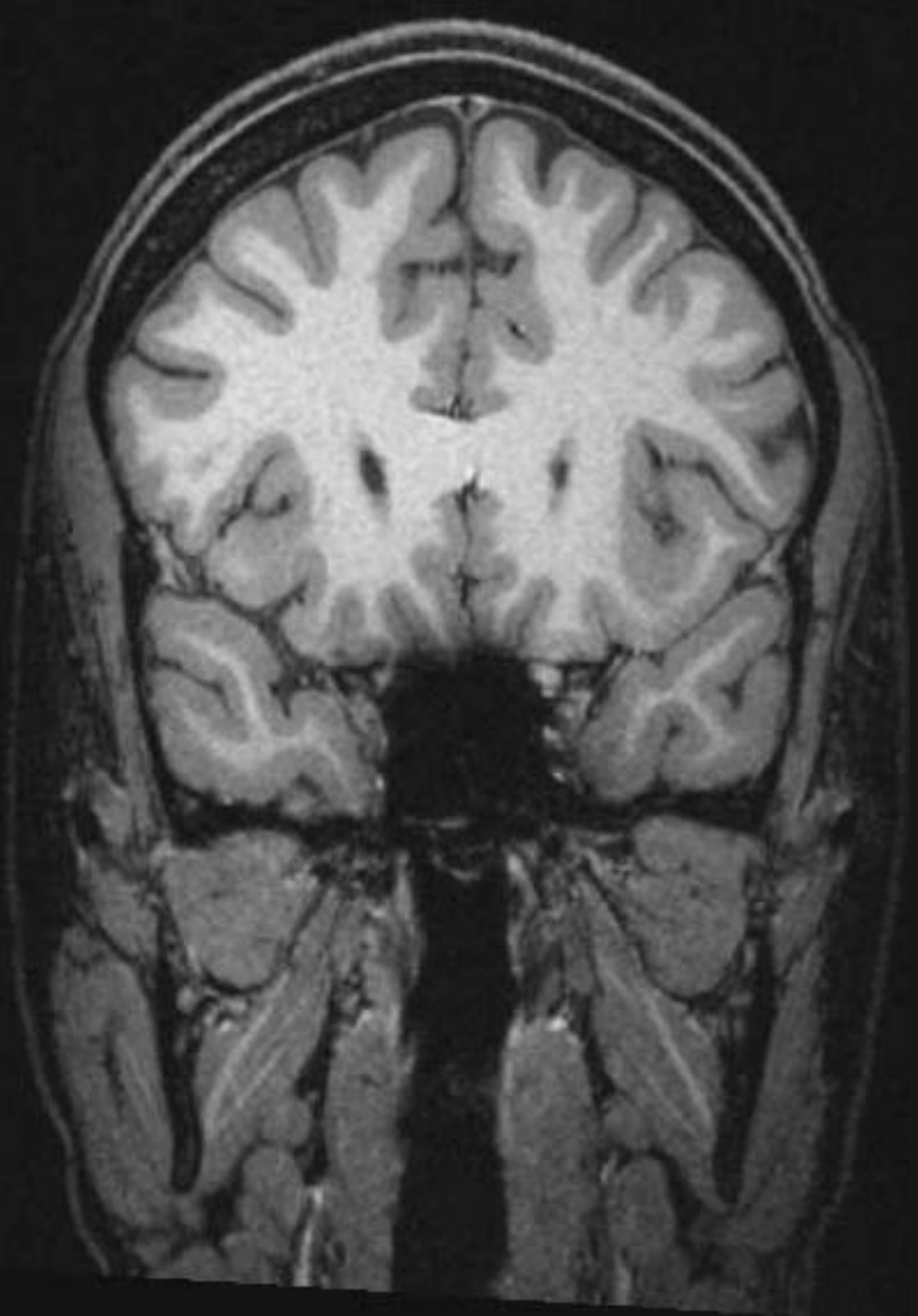
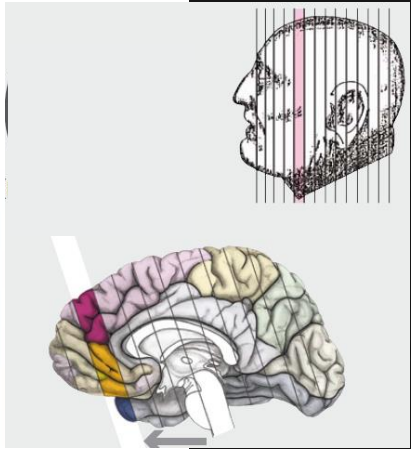
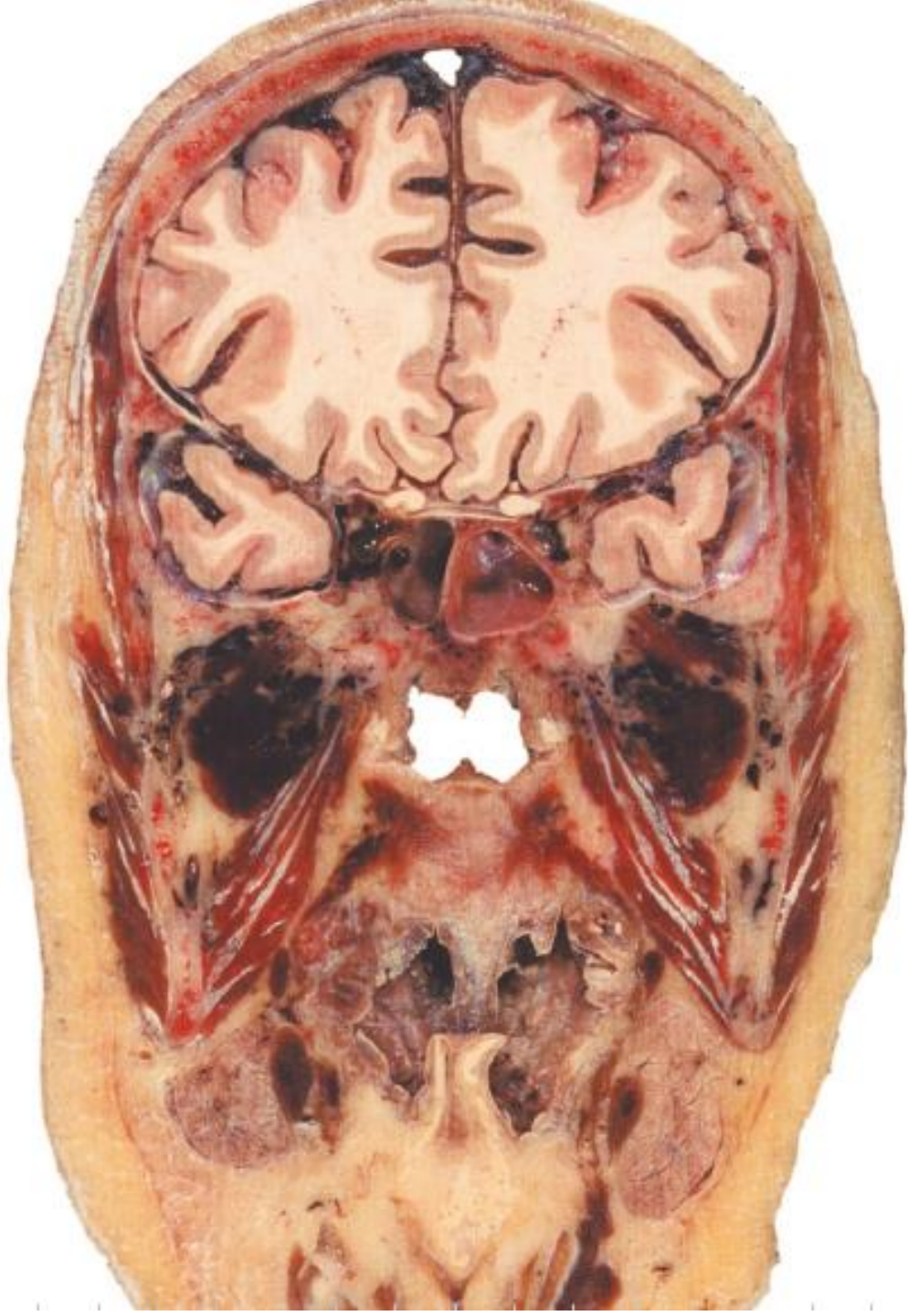CBP

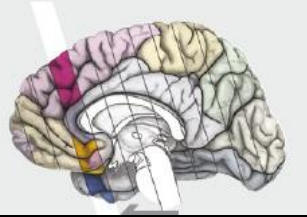
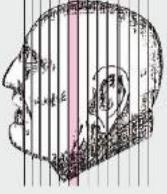
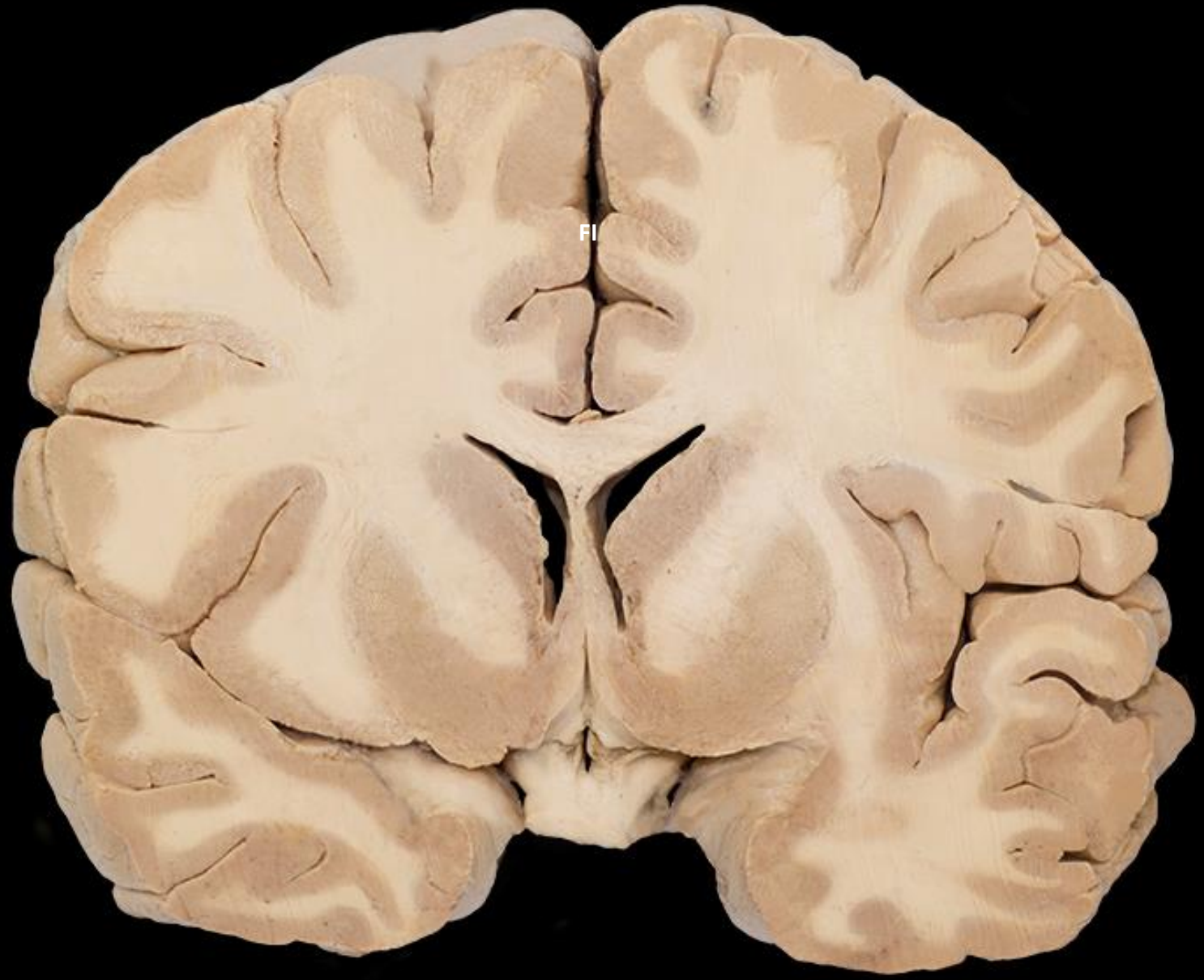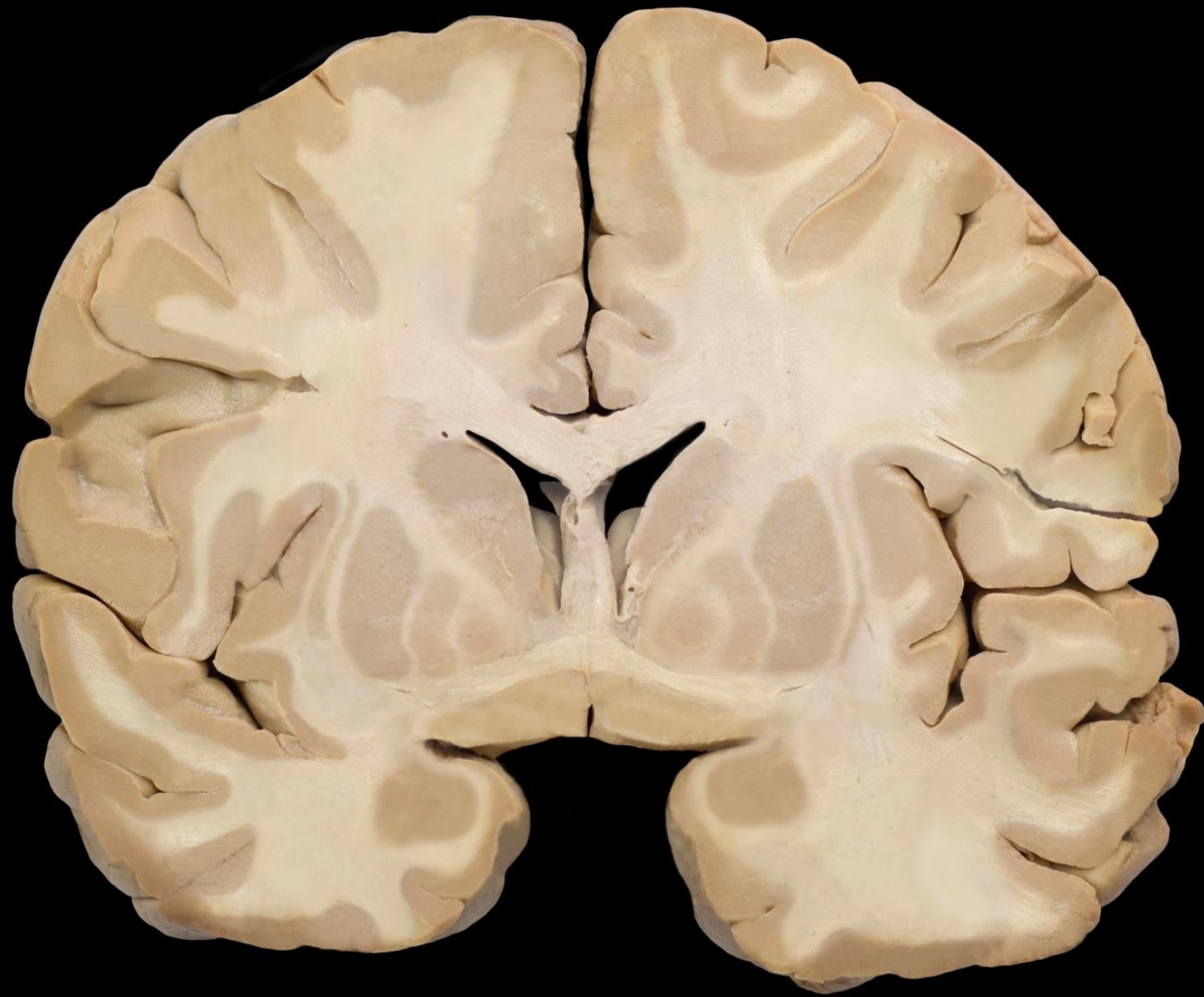


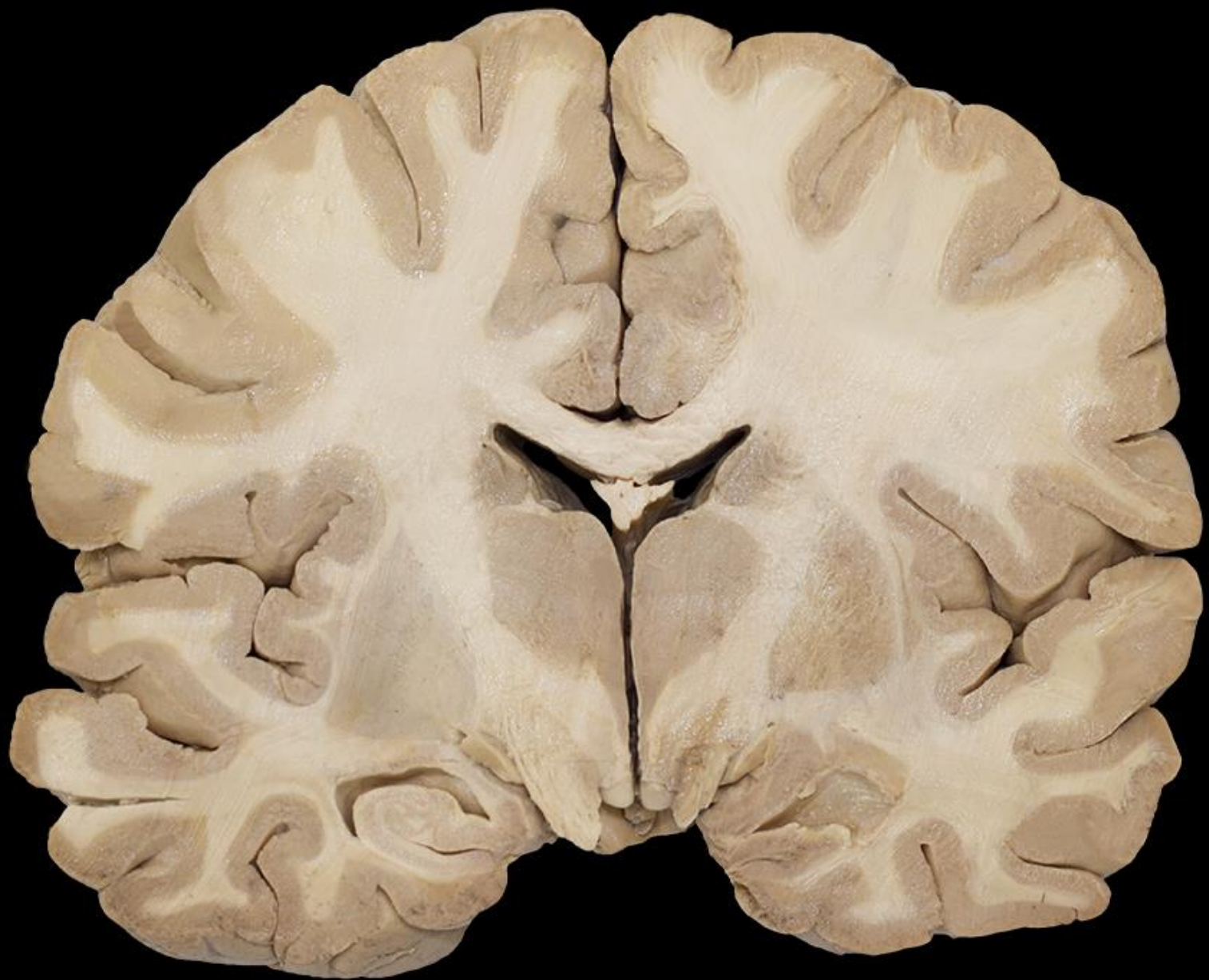




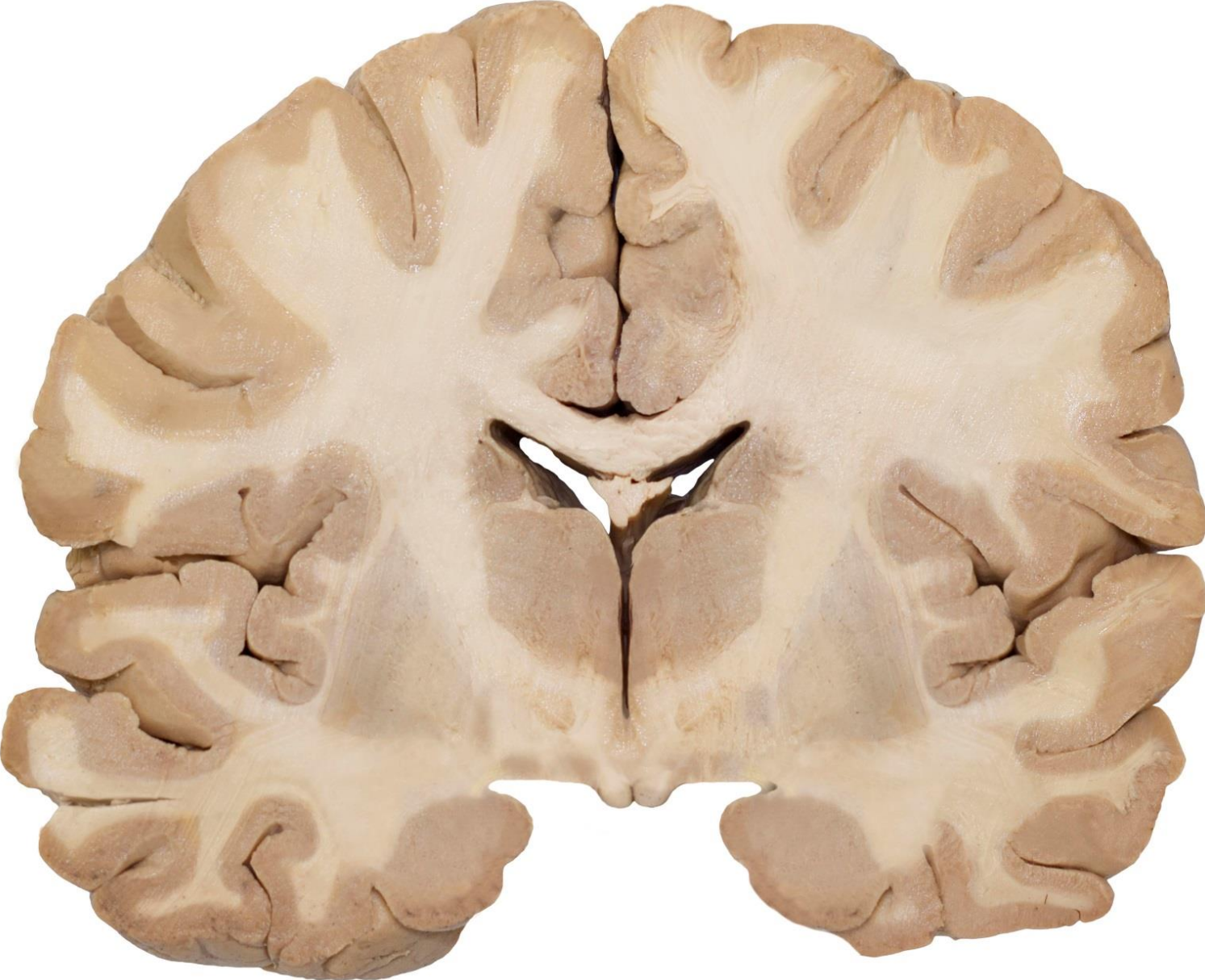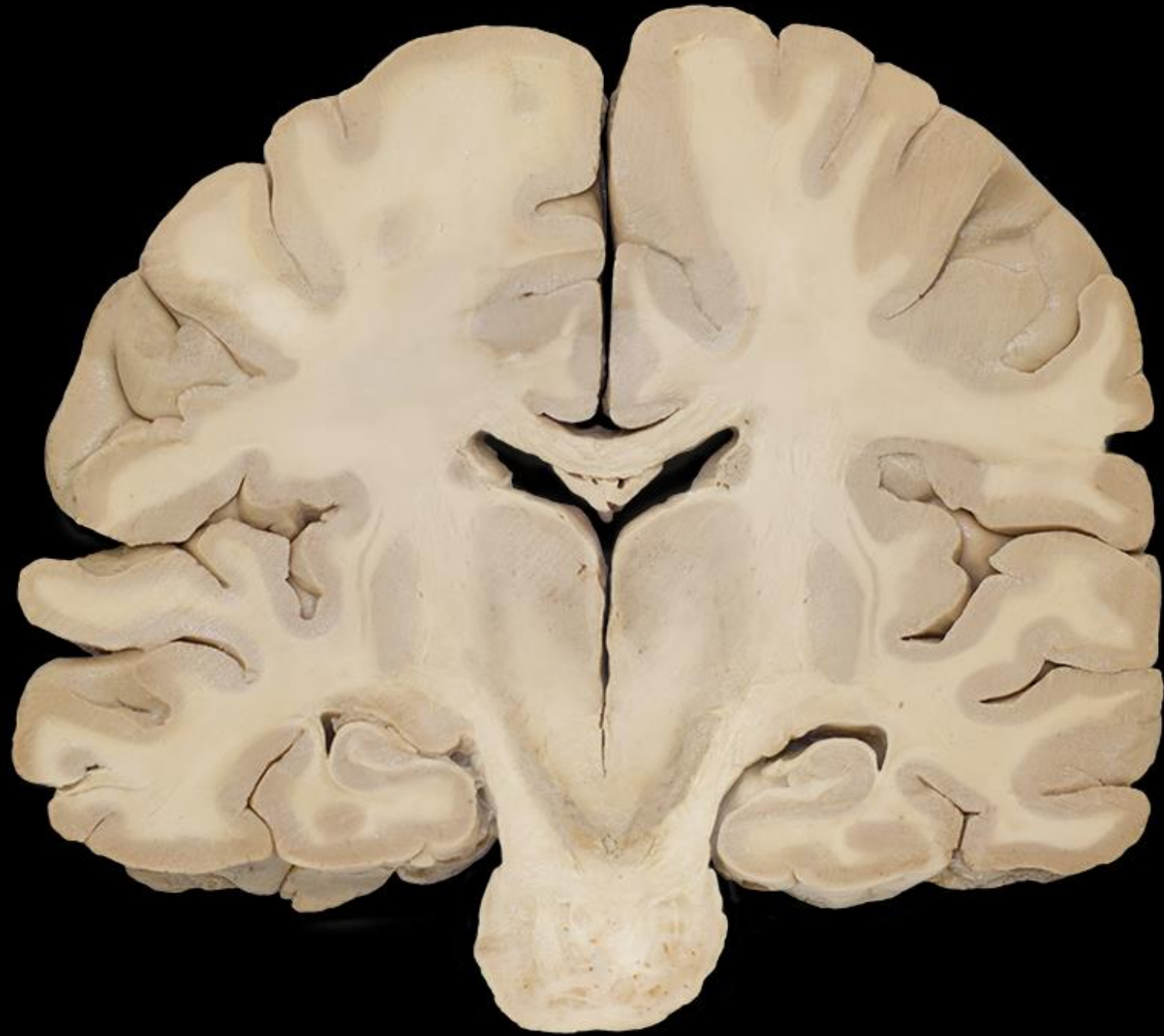




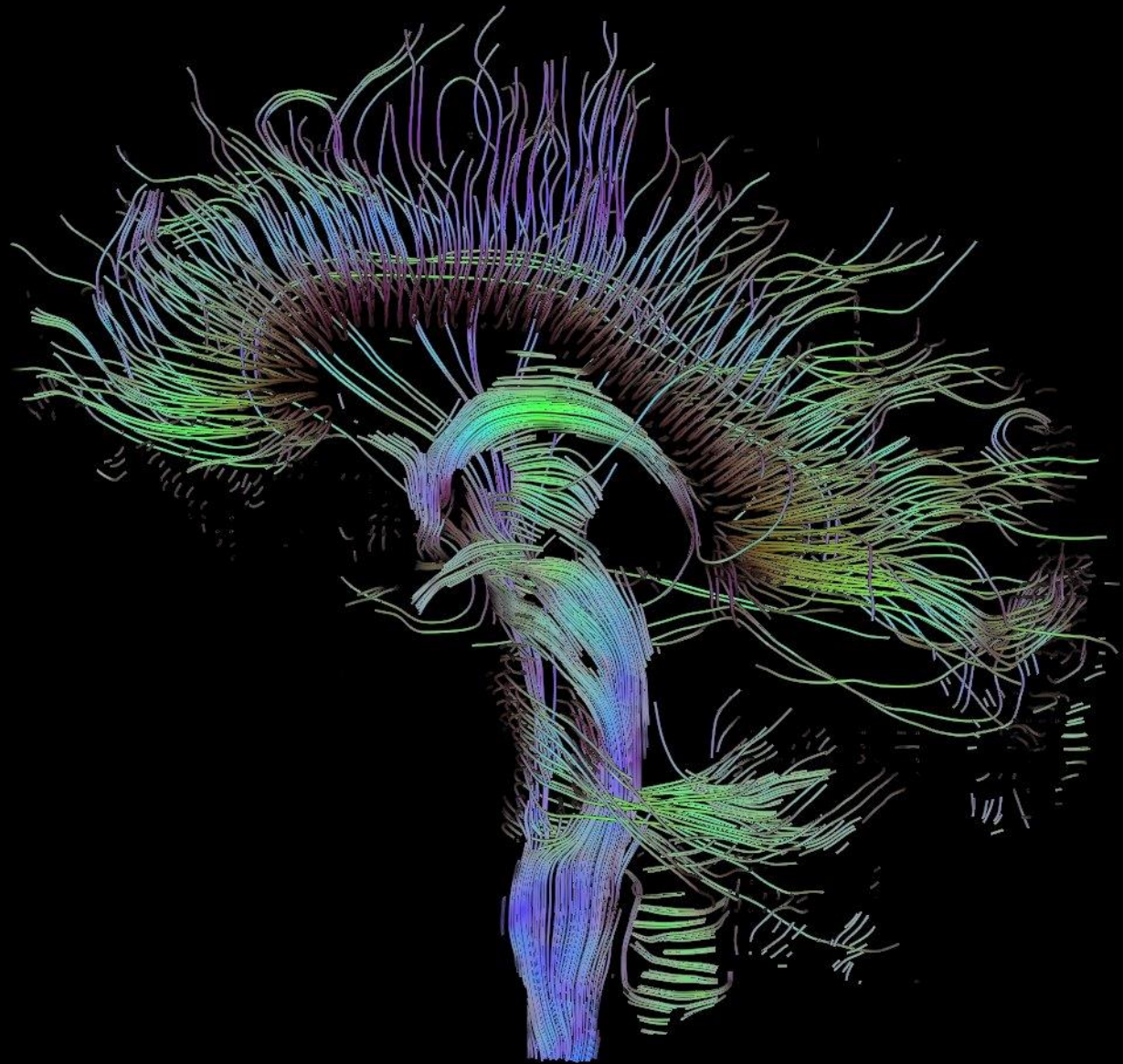






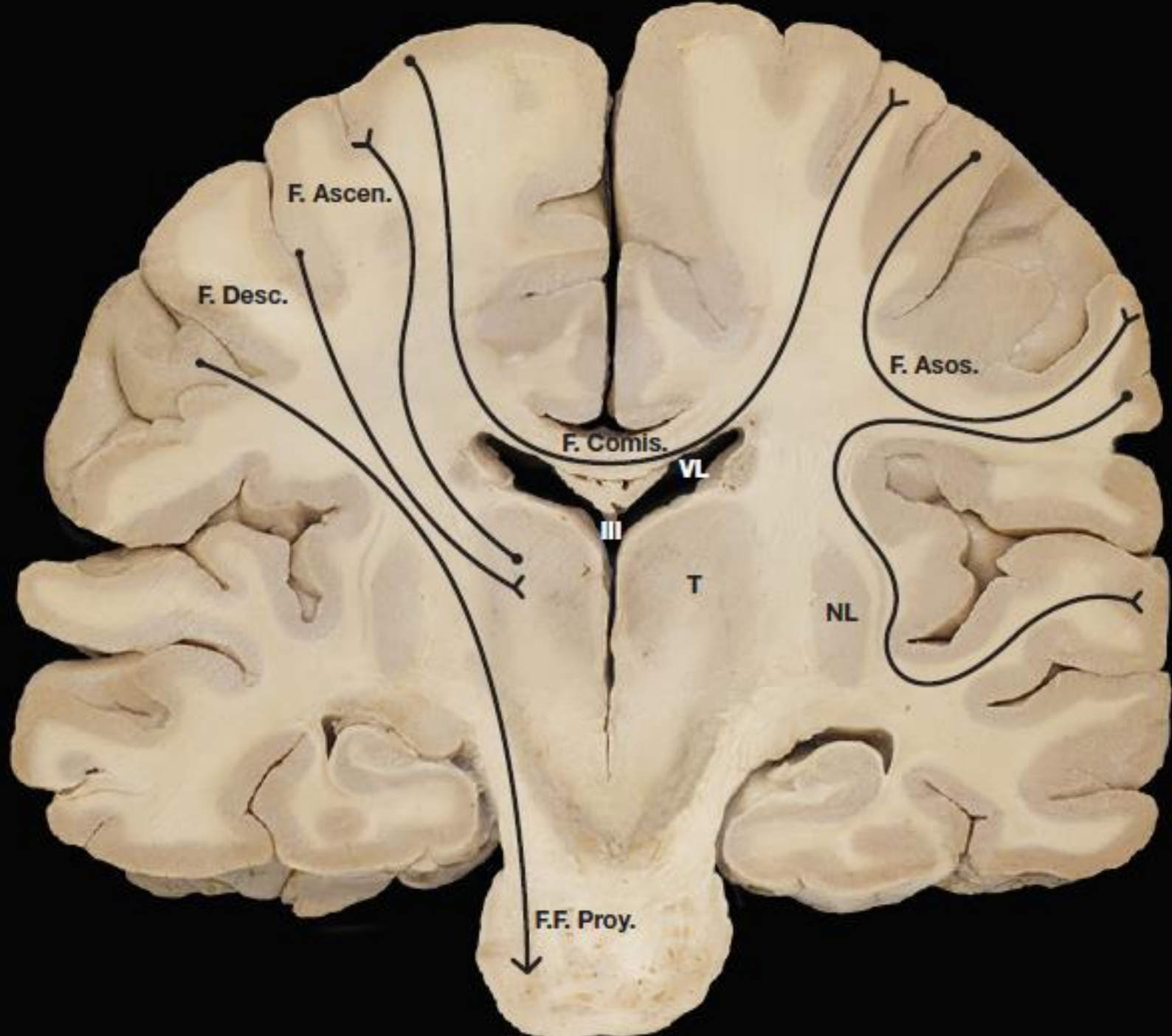


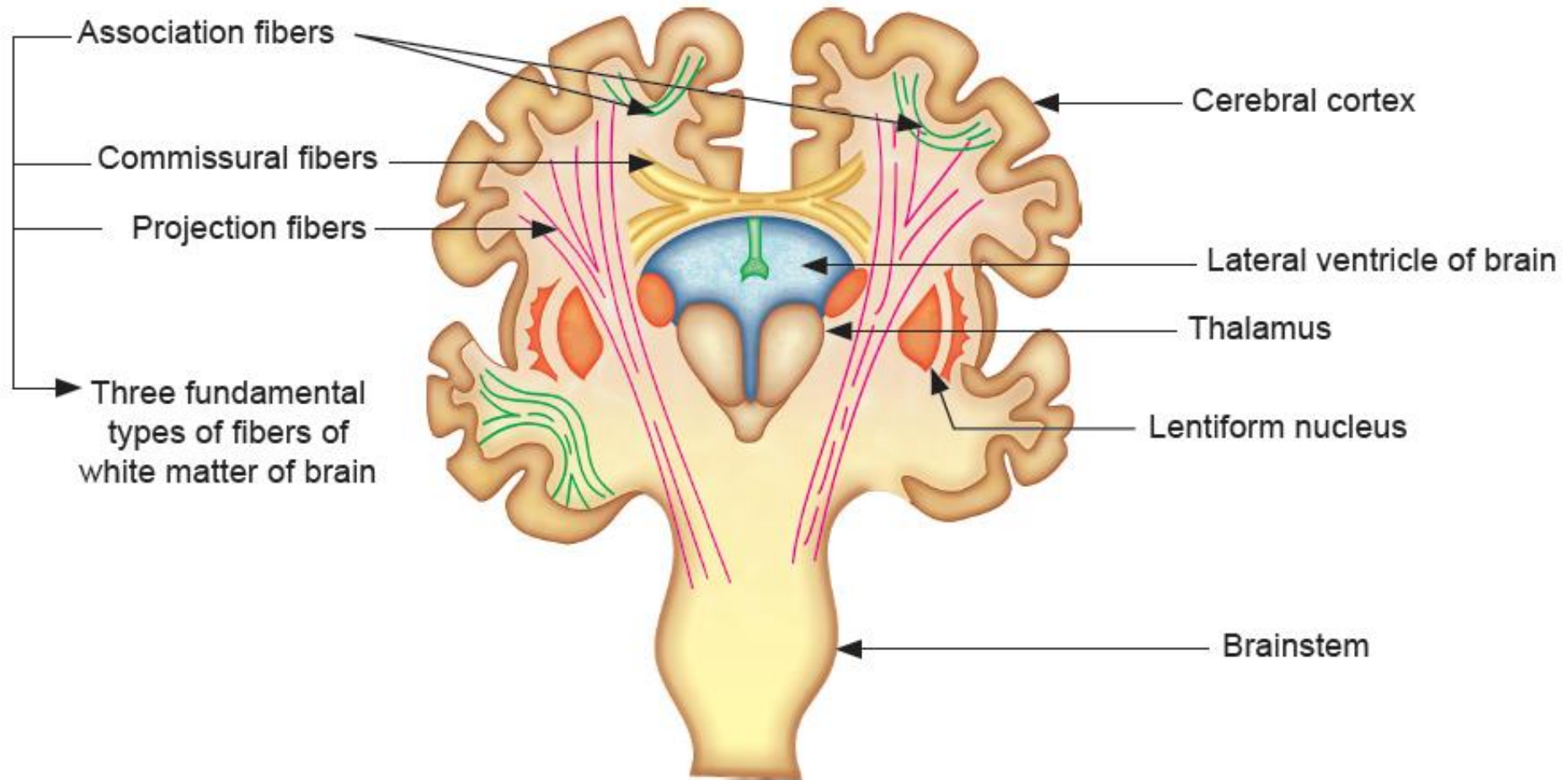
SUSTANCIA BLANCA SUBCORTICAL



Sustancia Blanca Subcortical

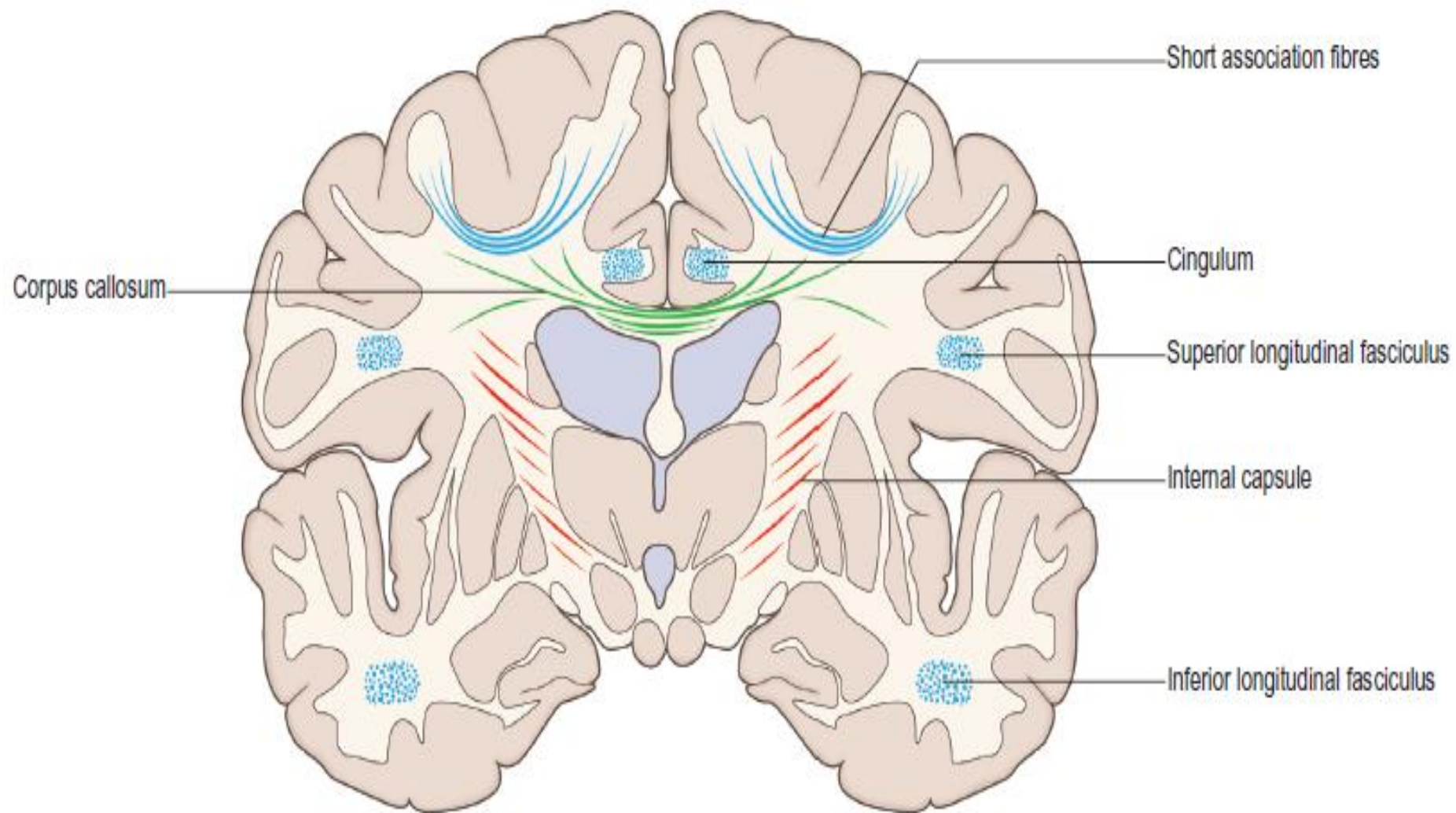
- Axones Horizontales (Fibras Asociativas)
- Axones Ascendentes (Aferencias Corticales)
- Axones Descendentes (Fibras Proyección)





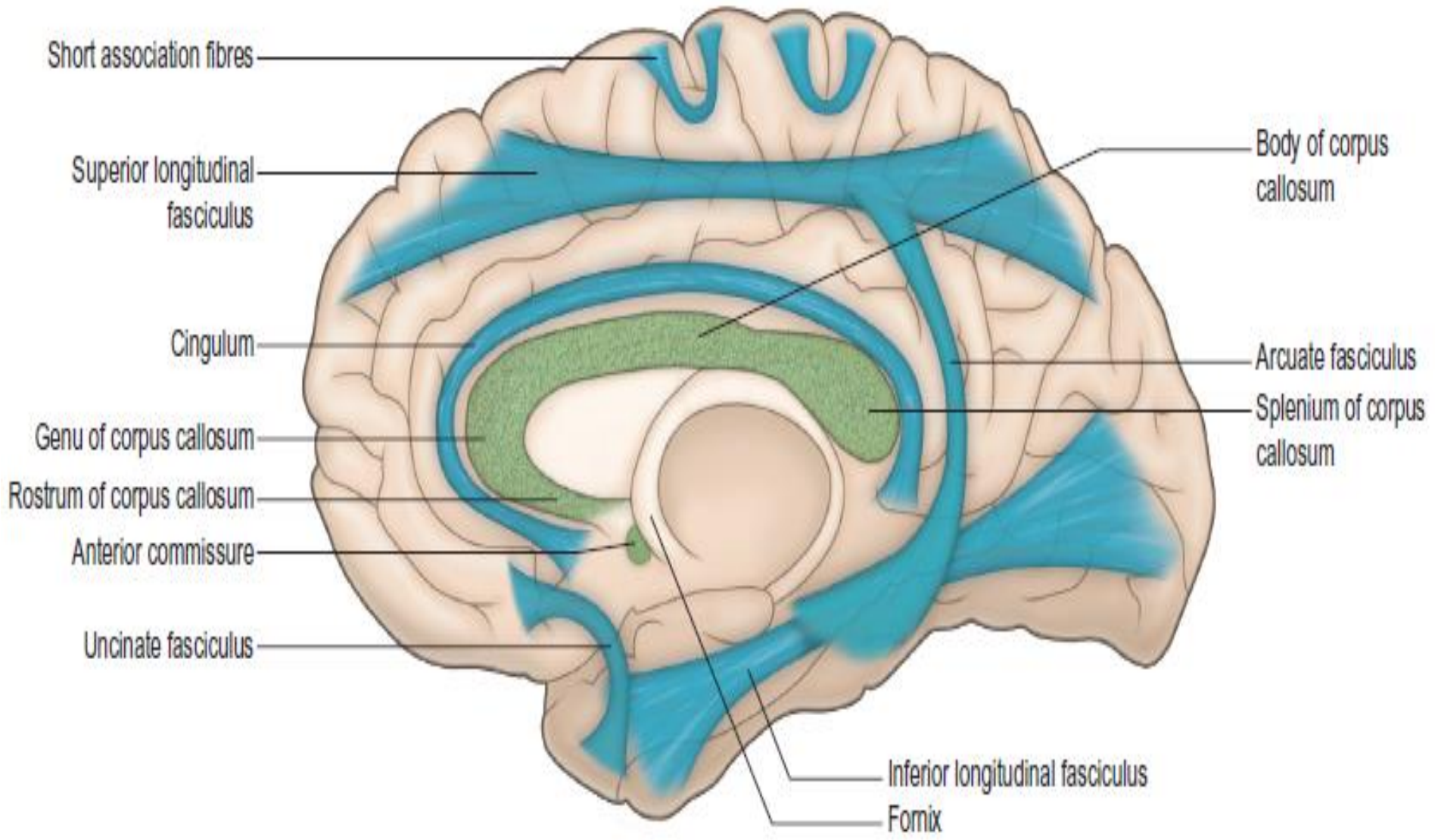
Fascículos Asociativos

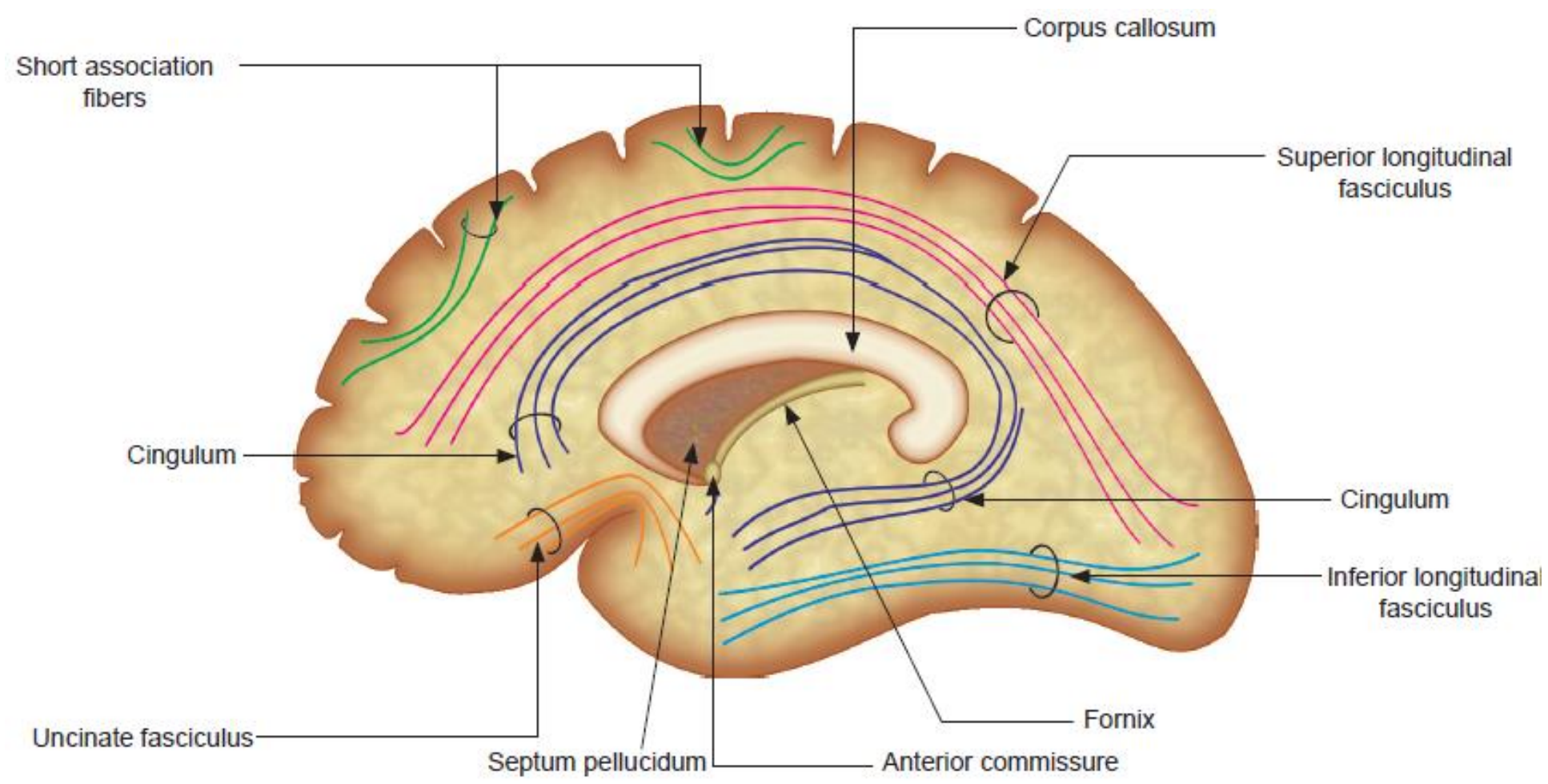
- Fibras Arcuadas Cortas
- Fibras Arcuadas Largas



Fascículos Asociativos

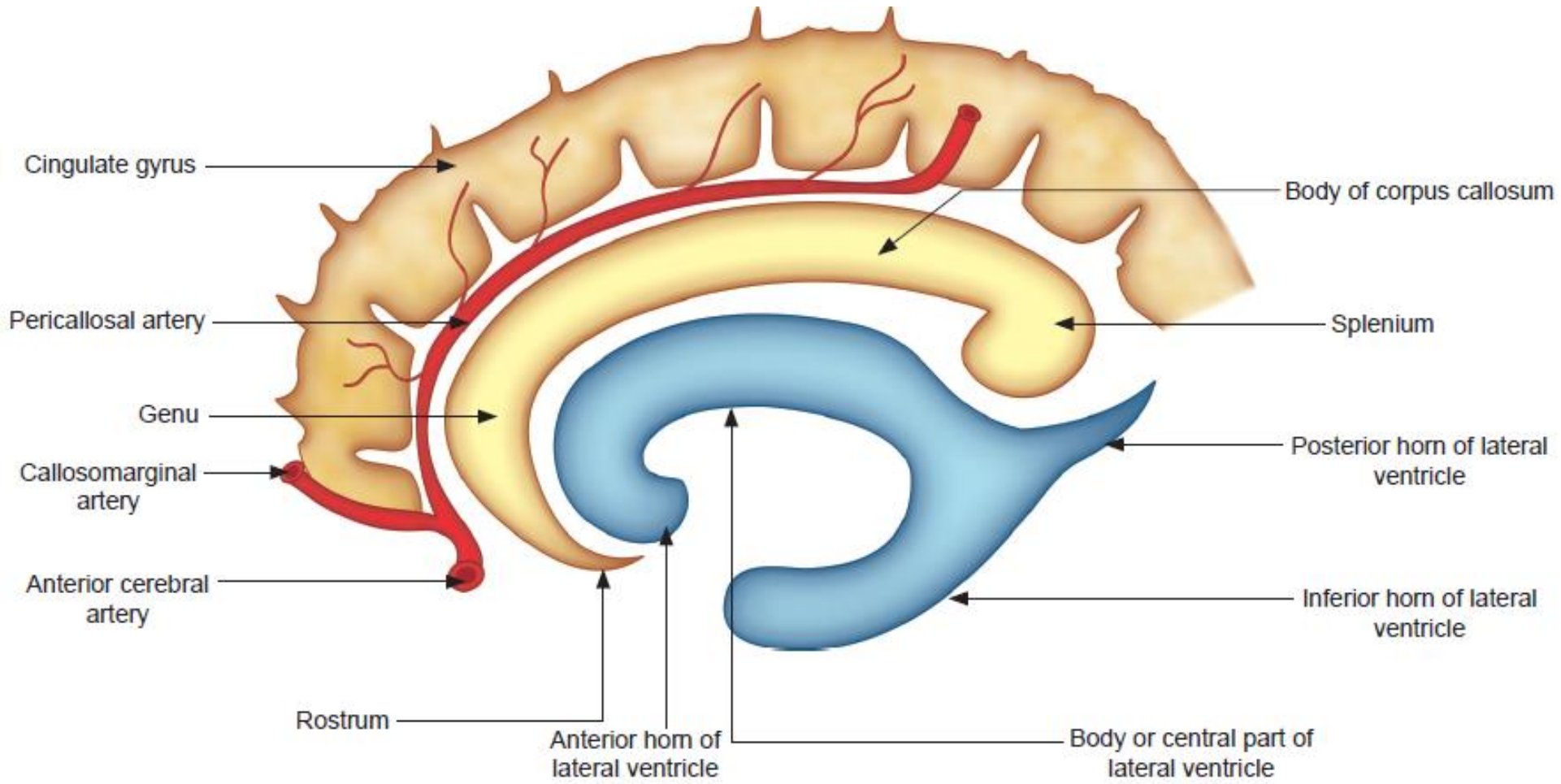
- Fascículo Longitudinal Superior
- Fascículo Longitudinal Inferior
- Fascículo Fronto-Occipital
- Fascículo Arcuado
- Fascículo Cíngulo





Fibras Comisurales

- Cuerpo Calloso
- Comisura Blanca Anterior
- Comisura Blanca Posterior
- *Parte del Fórnix*

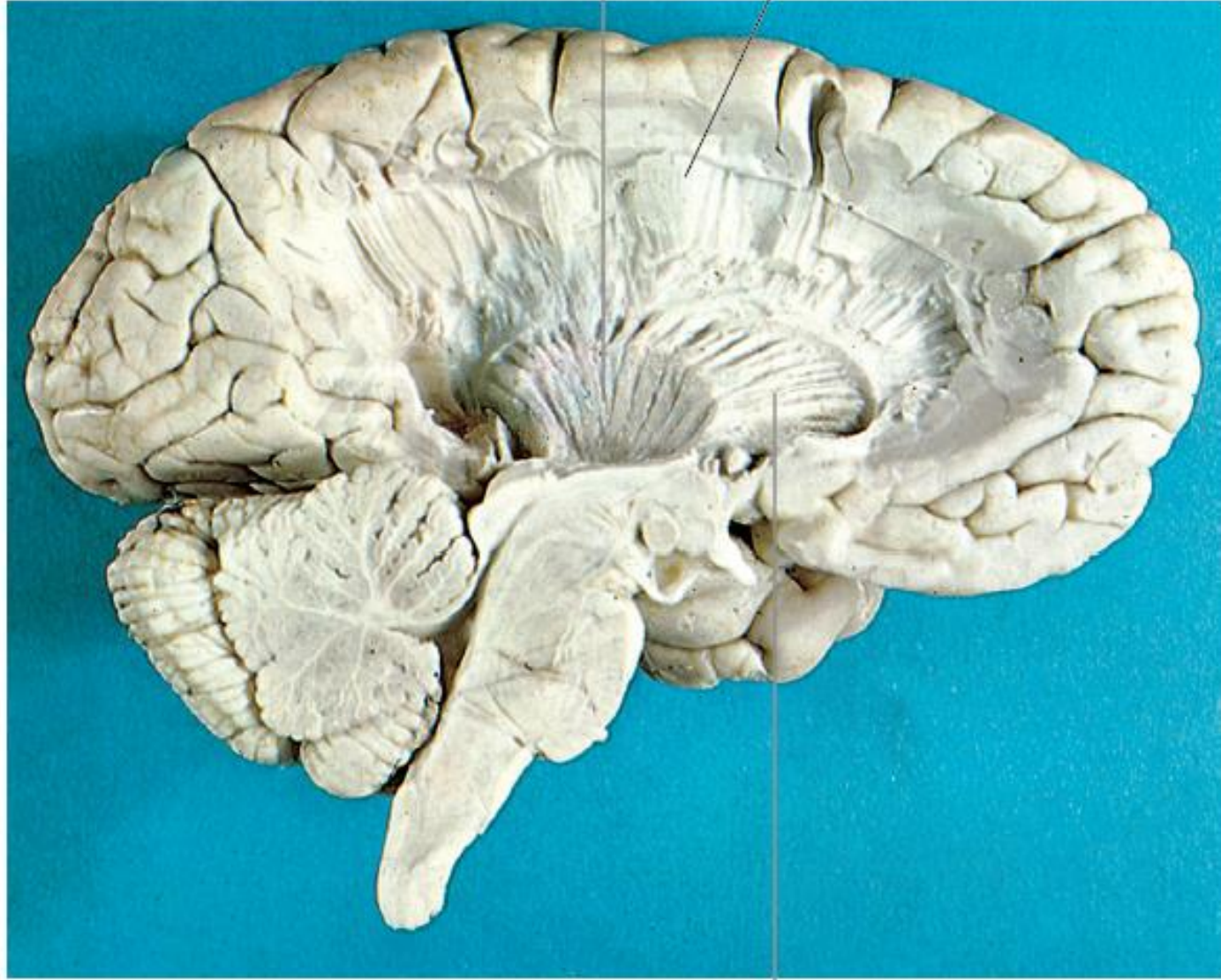


Fibras de Proyección

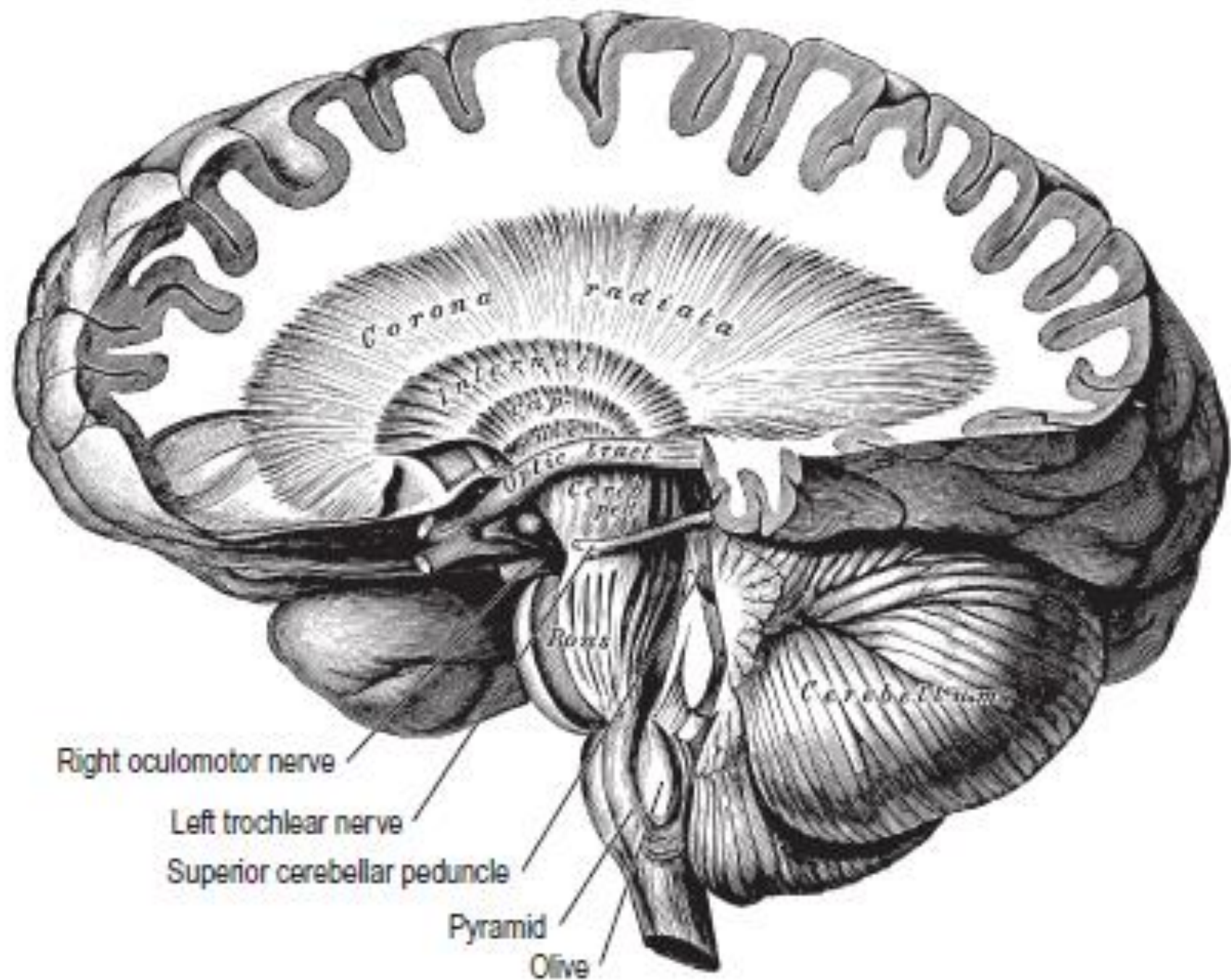
- Cápsula Interna

Posterior limb of
internal capsule

Corona radiata

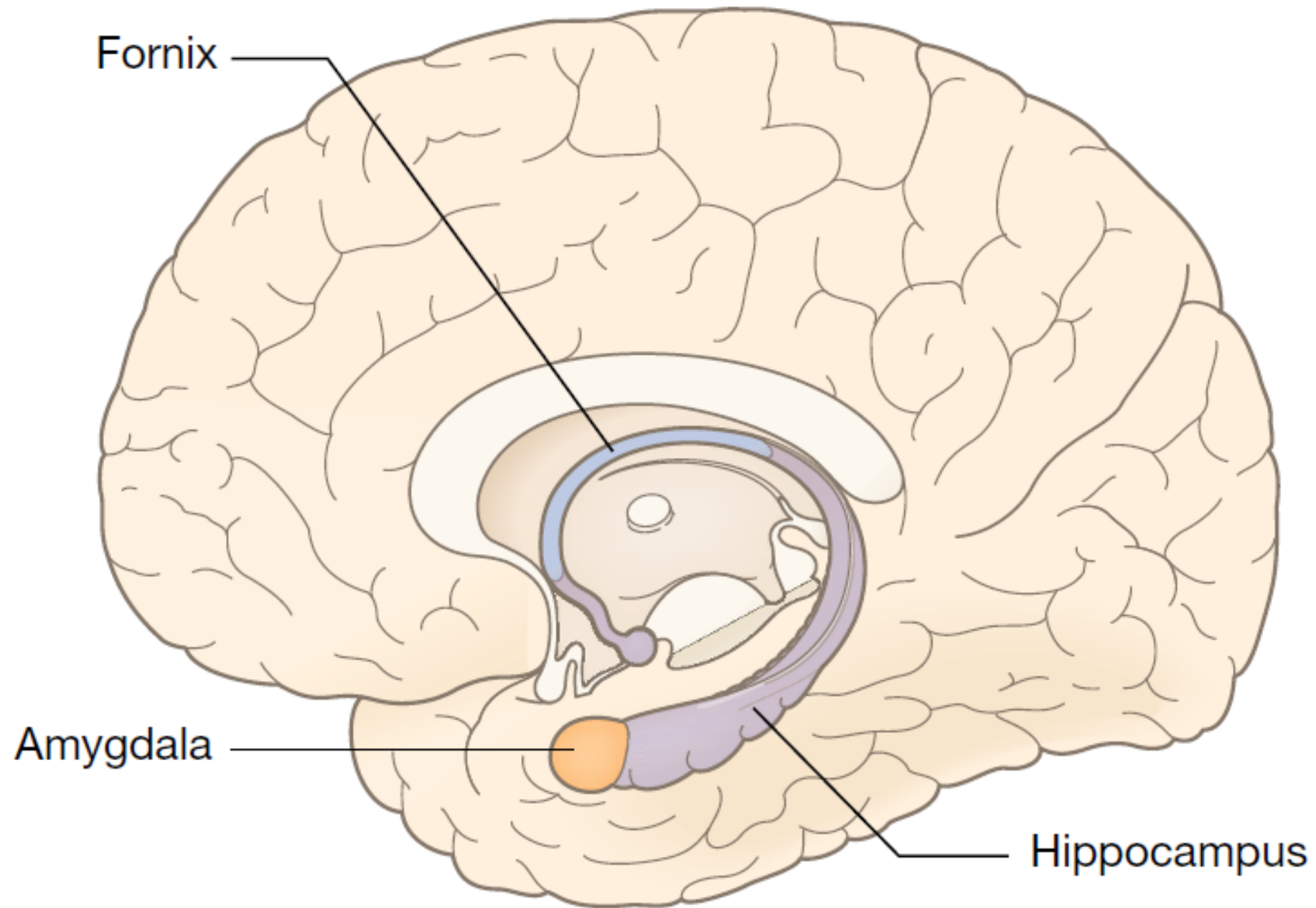


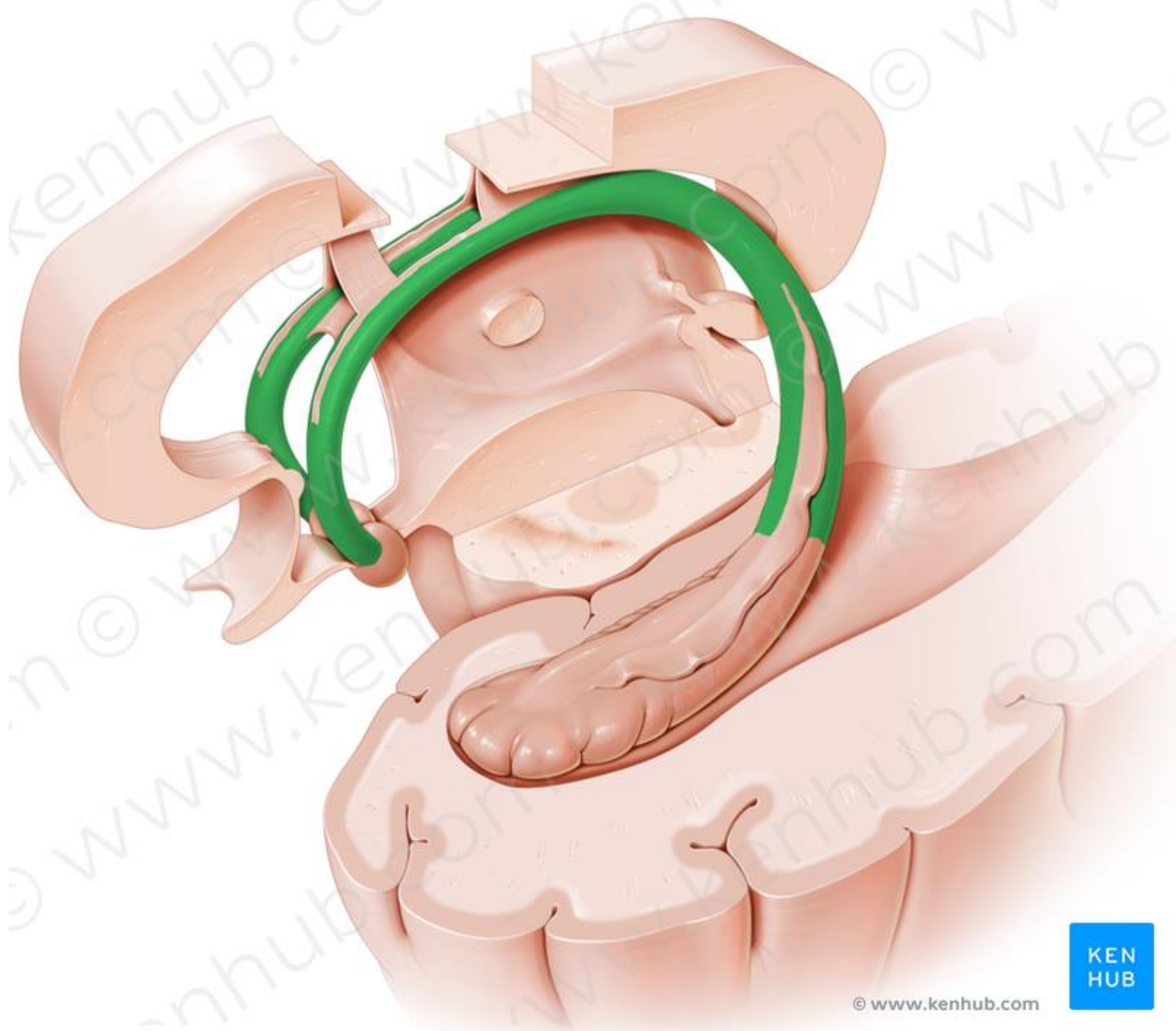
Anterior limb of
internal capsule

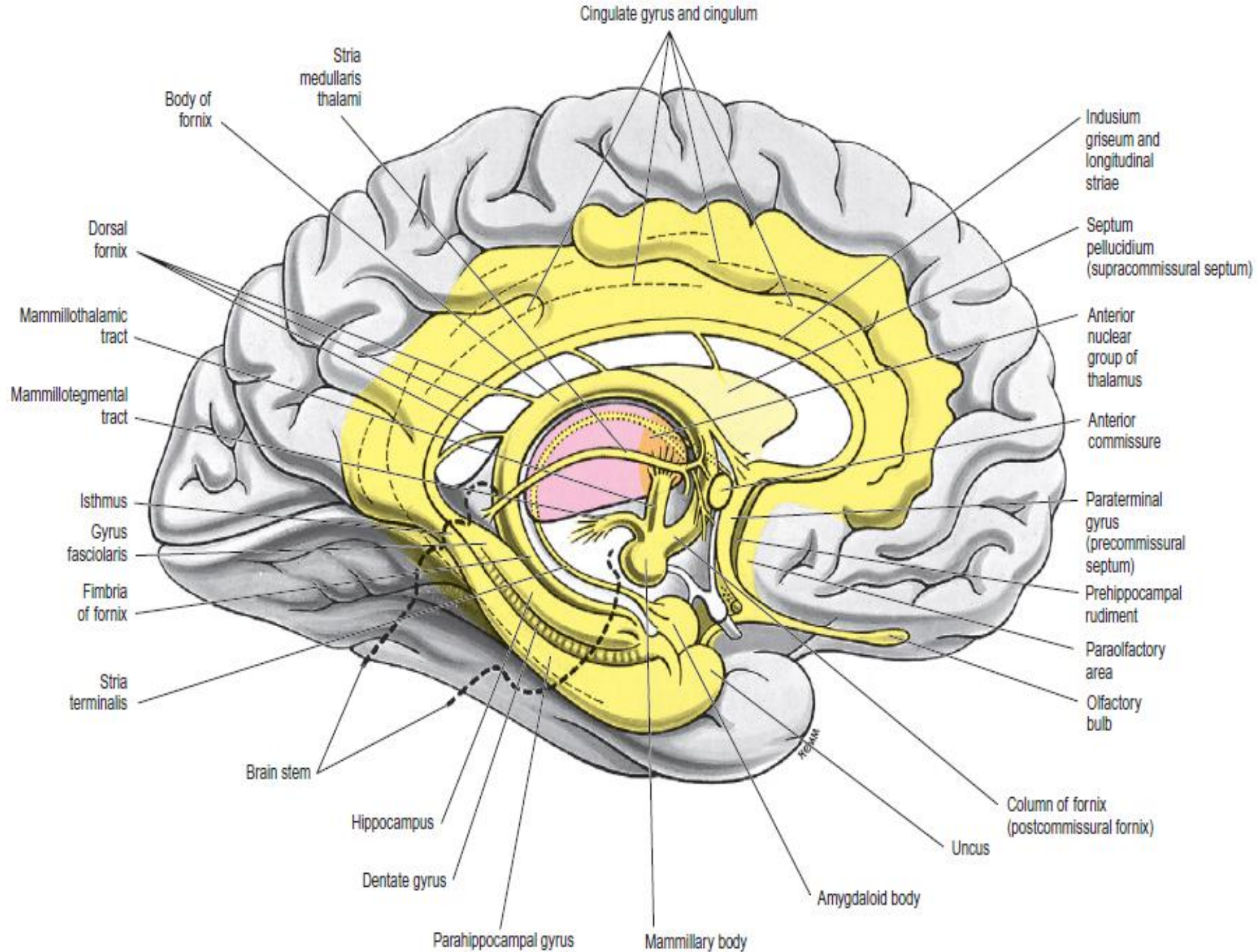


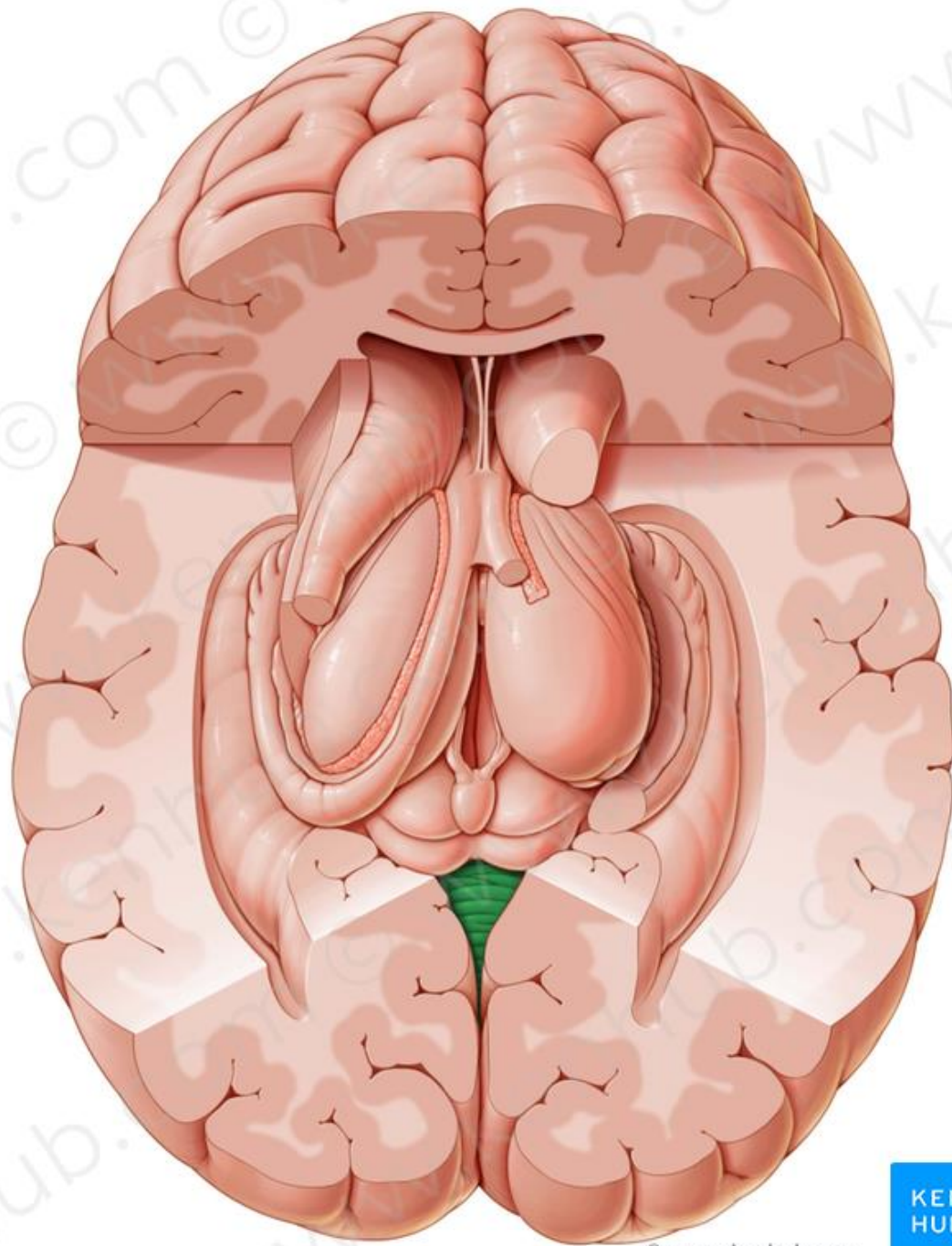
Otros Fascículos

- Fórnix
- Estría Terminal









PUES MIRE ...
SU MARIDO TIENE
UNA BRONCONEUMONÍA BILATERAL
DE PROBABLE ORIGEN NEUMOCÓCICO ...

CLARO ...
CON RAZÓN SE LE OÍAN ANOCHE
TANTOS ESTERTORES CREPITANTES
EN AMBOS CAMPOS ...



F. BAYONA